

# AGA Technical Review on Perianal Crohn's Disease

*This literature review and the recommendations therein were prepared for the American Gastroenterological Association Clinical Practice Committee. The paper was approved by the Committee on May 18, 2003, and by the AGA Governing Board on July 25, 2003.*

This report is a technical review of the normal anatomy, definitions, etiology, classification, epidemiology, diagnosis, disease activity assessment, and medical and surgical treatment of perianal Crohn's disease. Although descriptions of surgical therapy are provided along with the indications, outcomes, and complications of surgical intervention, the reader is cautioned that this review is not meant to provide the details of how to perform the specific individual surgical procedures.

## Strategy for Literature Identification

A search of the online bibliographic databases MEDLINE (1966 to August 2002) and Current Contents/Science Edition (1996 to August 2002) was performed to identify potentially relevant English-language articles. The Medical Subject Heading terms "Crohn's disease" or "inflammatory bowel disease" or "regional enteritis" AND "fistulas" or "perianal" were used to perform keyword searches of the database. Manual searches of the reference lists from the potentially relevant papers and the proceedings from annual meetings of the American Gastroenterological Association, American College of Gastroenterology, and American Society of Colon and Rectal Surgeons from 1990 to 2003 were performed to identify additional studies that may have been missed using the computer-assisted search strategy. Studies selected were retrospective or prospective studies reporting on the classification, epidemiology, diagnosis with magnetic resonance imaging (MRI) or anorectal endoscopic ultrasonography (EUS), treatment with medical therapy, and surgical treatment of perianal Crohn's disease. This technical review is not based solely on level 1 studies (population-based natural history studies and randomized, double-blind, placebo-controlled trials of diagnostic modalities and therapeutic interventions), because only 5 level 1 studies were identified and they do not provide a sufficient basis for an "evidence-based" technical review and medical position statement. Therefore, this technical review represents the consensus opinion of the authors based on a comprehensive review of the best available evidence.

## Normal Anatomy, Definitions, Etiology, and Classification

### Normal Anatomy

To understand the etiology and classification of perianal fistulas and other perianal lesions, a review of perianal anatomy is required. The anal canal consists of an inner layer of circular smooth muscle extending downward from the rectum called the internal anal sphincter, the intersphincteric space, and an outer layer of skeletal muscle extending downward from the puborectalis and levator ani muscles called the external anal sphincter (Figure 1). The dentate line, located in the midportion of the anal canal, separates the transitional and columnar epithelium of the rectum from the squamous epithelium of the anus. Anal crypts are located at the dentate line, and anal glands are found at the base of these crypts.

### Definitions

The definitions for the various types of perianal lesions that occur in patients with Crohn's disease are shown in Table 1. A perianal fistula (Latin for pipe) is a chronic track of granulation tissue connecting 2 epithelial lined surfaces.<sup>1</sup> A sinus track is a track of granulation tissue that is open only at one end.

### Etiology and Classification of Fistula-in-Ano

In patients without Crohn's disease, perianal fistulas (often called fistula-in-ano or cryptogenic fistulas) usually arise from infected anal glands.<sup>2</sup> In 1934, Milligan and Morgan classified fistula-in-ano according to their relationship to the anorectal ring (formed by the puborectalis muscle) as subcutaneous, low anal (below the dentate line), high anal (above the dentate line but below the anal ring formed by the puborectalis muscle), anorectal below the levator ani muscle (ischioanal or

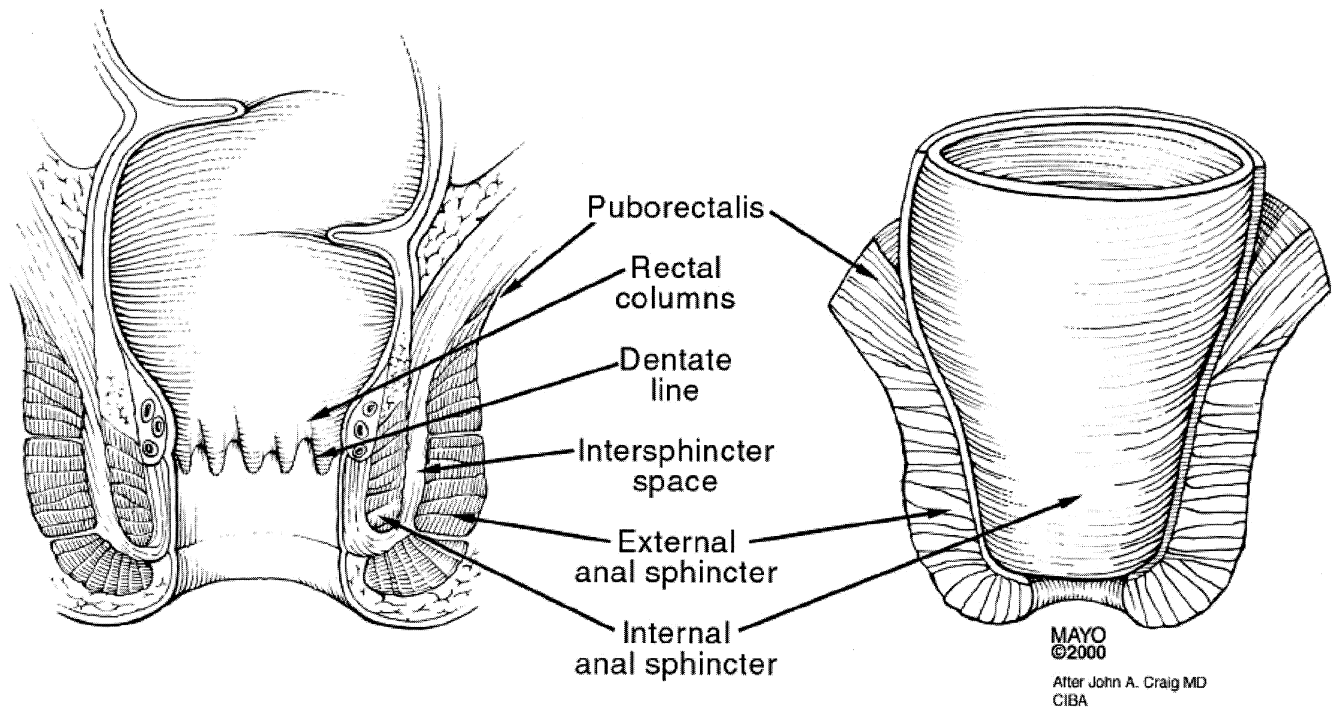
---

*Abbreviations used in this paper:* EUA, examination under anesthesia; EUS, endoscopic ultrasonography; MRI, magnetic resonance imaging.

© 2003 by the American Gastroenterological Association

0016-5085/03/\$30.00

doi:10.1053/S0016-5085(03)01367-2



**Figure 1.** Schematic diagram of anatomic relationships in the perianal region. Modified and reprinted with permission from Fry RD, Kodner JJ. Anorectal disorders. Clin Symp 1985;37:2–32.

infralelevator), anorectal above the levator ani muscle (pelvirectal or supralelevator), and submucous (high intermuscular between the internal and external anal sphincters).<sup>3</sup> Most fistulas-in-ano originate below the dentate line, and many colorectal surgeons simply classify them as low or high.<sup>1</sup> In 1976, Parks et al. proposed a more anatomically precise classification system for fistula-in-ano that uses the external sphincter as a central point of reference (Figure 2).<sup>4</sup> The Parks classification describes 5 types of perianal fistulas: intersphincteric, transsphincteric, suprasphincteric, extrasphincteric, and superficial (Figure 2). The presence of any branching or horseshoeing (crossing the midline anteriorly or posteriorly) and its location (intersphincteric, infralelevator, and supralelevator) must also be noted.

### Etiology and Classification of Perianal Crohn's Disease

In patients with Crohn's disease, a variety of perianal manifestations may occur, including perianal skin lesions (anal skin tags, hemorrhoids), anal canal lesions (anal fissures, anal ulcers, anorectal strictures), perianal fistulas and abscesses, rectovaginal fistulas, and cancer.<sup>5,6</sup> The etiology of Crohn's perianal fistulas may be a fistula-in-ano arising from inflamed or infected anal glands and/or penetration of fissures or ulcers in the rectum or anal canal.<sup>2,6</sup> In 1978, Hughes proposed an anatomic and pathologic classification for perianal

Crohn's disease (the Cardiff classification) in which each major manifestation of perianal Crohn's disease (ulceration, fistula, and stricture) is graded on a scale of 0 to 2 (0, absent; 2, severe); fistulas are also classified as low (not extending above the dentate line) or high (extending above the dentate line, sometimes to the levator muscles), and other associated anal conditions, the intestinal location of other sites of Crohn's disease, and a global assessment of the activity of the perianal disease are noted (Tables 2 and 3).<sup>6,7</sup> Despite its descriptive accuracy and comprehensiveness, the Cardiff classification system has never gained widespread acceptance because of the perception by clinicians that it is of limited clinical relevance.<sup>8,9</sup> Neither the Cardiff classification nor a more recent perianal Crohn's Disease Activity Index score have been reproduced or prospectively validated using clinically meaningful end points.<sup>10</sup>

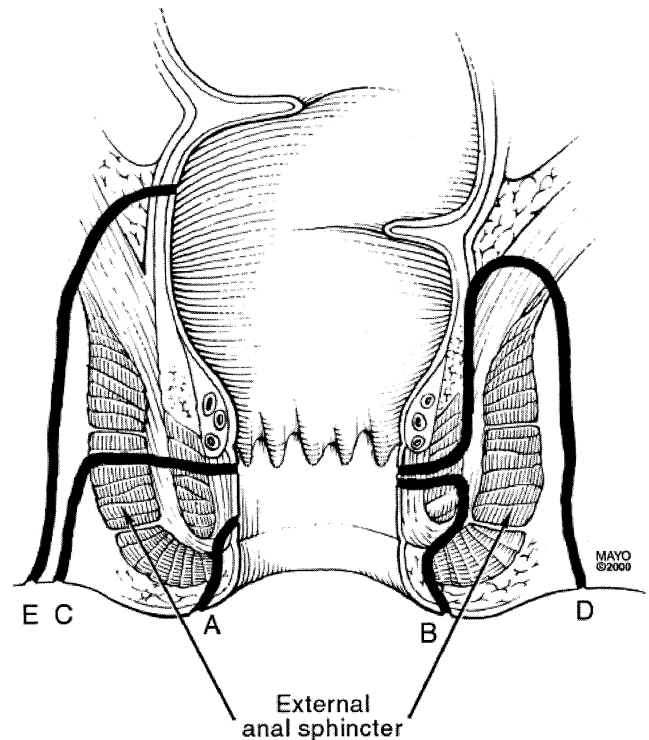
These perianal disease classifications or indices of activity have yet to be standardized or used in clinical practice. The Parks classification system can be used to classify and describe perianal fistulas, but it does not address the other perianal manifestations of Crohn's disease. We propose an empiric approach that we believe is relatively widely used. This empiric approach includes physical examination of the perianal area to identify anal skin tags, anal fissures, perianal fistulas, suspected perianal abscesses, anorectal strictures, and rectovaginal fis-

**Table 1.** Definition of Various Types of Perianal Lesions in Patients With Crohn's Disease

Type of lesion	Description
Skin tag	Two types: 1. Large, edematous, hard, cyanotic skin tags. Typically arising from a healed anal fissure or ulcer. Excision contraindicated due to problems with wound healing. 2. "Elephant ear" tags that are flat and broad or narrow, soft painless skin tags. May cause perianal hygiene problems and can be safely excised.
Hemorrhoids	Prolapsing internal hemorrhoids. Uncommon in Crohn's disease. Often present as large external skin tags.
Fissure	Anal fissures are broad based and deep with undermining of the edges. There may be associated large skin tags and a cyanotic hue to the surrounding skin. They tend to be multiple and may be placed either eccentrically around the anal canal or in the midline in contrast to idiopathic fissure-in-ano, which tend to lie in the midline. Typically painless (pain should raise suspicion for perianal abscess or acute/chronic conventional anal fissure). Conventional anal fissures occasionally are treated by conventional fissure treatment including lateral sphincterotomy.
Anal ulcer	Anal ulcers are usually associated with rectal inflammation and may lead to destruction of the anorectum, anorectal strictures, complex anorectal fistulas, and perianal abscess.
Low fistula	Superficial, low intersphincteric, or low transsphincteric fistulas. May arise from either the anal glands (cryptogenic) or from penetrating ulceration of the anal canal or rectum.
High fistula	High intersphincteric, high transsphincteric, suprasphincteric, extrasphincteric fistulas. Arise from penetrating ulceration of the anal canal or rectum.
Rectovaginal fistula	Superficial, intersphincteric, transsphincteric, suprasphincteric, extrasphincteric fistulas. Arise from penetrating ulceration of the anal canal or rectum into the vagina.
Perianal abscess	Potential anorectal spaces may become infected with an abscess, including perianal, ischioanal, deep postnatal, intersphincteric, and supralevator.
Anorectal stricture	May be short annular diaphragm-like strictures <2 cm in length or longer tubular strictures arising from rectal inflammation. May arise from either the anal glands (cryptogenic) or from penetrating ulceration of the anal canal or rectum.
Cancer	Squamous cell carcinoma, basal cell carcinoma, or adenocarcinoma arising from malignant degeneration of nonhealing perianal fistulas or sinus tracts.

cial or low intersphincteric or low transsphincteric origin of the fistula tract), has a single external opening, has no pain or fluctuation to suggest perianal abscess, has no evidence of a rectovaginal fistula, and has no evidence of anorectal stricture. The presence of active rectal Crohn's disease may make a simple fistula more complicated to manage. Patients with simple fistulas may have higher rates of healing.<sup>11</sup>

A complex fistula is high (high intersphincteric or high transsphincteric or extrasphincteric or suprasphincteric origin of the fistula tract), may have multiple external openings, may be associated with the presence of pain or fluctuation to suggest a perianal abscess, may be associated with the presence of a rectovaginal fistula, may be associated with the presence of an anorectal stricture, and may be associated with the presence of active rectal disease at endoscopy. Additional diagnostic evaluation with examination under anesthesia (EUA), anorectal



**Figure 2.** The Parks classification. (A) A superficial fistula tracks below both the internal anal sphincter and external anal sphincter complexes. (B) An intersphincteric fistula tracks between the internal anal sphincter and the external anal sphincter in the intersphincteric space. (C) A transsphincteric fistula tracks from the intersphincteric space through the external anal sphincter. (D) A suprasphincteric fistula leaves the intersphincteric space over the top of the puborectalis and penetrates the levator muscle before tracking down to the skin. (E) An extrasphincteric fistula tracks outside of the external anal sphincter and penetrates the levator muscle into the rectum. Modified and reprinted with permission from Parks et al.<sup>4</sup> © British Journal of Surgery Society Ltd. Reproduced with permission. Permission is granted by John Wiley & Sons Ltd on behalf of the BJSS Ltd.

tulas as well as an endoscopic evaluation to determine whether or not there is macroscopically evident inflammation of the rectum. Fistulas are then classified as either "simple" or "complex." A simple fistula is low (superfi-

**Table 2.** Hughes/Cardiff 1979 Classification of Anal Crohn's Disease (U.F.S.)

Ulceration (U)	Fistula/abscess (F)	Stricture (S)
Not present-0	Not present-0	Not present-0
Superficial fissures-1	Lower/superficial-1	Reversible stricture (spasm/membranous)
a. Posterior and/or anterior	a. Perianal	a. Anal canal-spasm
b. Lateral	b. Anovulval, anoscrotal	b. Low rectum-membranous
c. With gross skin tags	c. Intersphincteric	c. Spasm with severe pain, no sepsis identified
Cavitating ulcers-2	d. Anovaginal	Irreversible stricture (severe fibrotic)-2
a. Anal canal	High/complex-2	a. Anal stenosis
b. Lower rectum	a. Blind supralelevator	b. Extrarectal stricture
c. With extension to perineal skin (aggressive ulceration)	b. High direct (anorectal)	
	c. High complex	
	d. Rectovaginal	
	e. Ileoperineal	

Modified and reprinted with permission from Hughes LE.<sup>6</sup>

EUS, and pelvic MRI may be required to accurately classify some patients (see following text).

### Epidemiology

In a combined medical and surgical Crohn's disease follow-up clinic, 110 of 202 consecutive patients (54%) had evidence of past or current perianal complications.<sup>12</sup> The types and distribution of perianal lesions are shown in Table 4.

The cumulative frequency of perianal fistulas in patients with Crohn's disease has been reported to range from 14% to 38% in patients evaluated at referral centers,<sup>13–18</sup> from 17% to 28% in patients undergoing surgery for Crohn's disease,<sup>19–21</sup> 36% in patients participating in a clinical trial,<sup>22</sup> and 13% in children and adolescents at a referral center.<sup>23</sup> Two population-based studies by Hellers et al. and Schwartz et al. have reported that perianal fistulas occurred in 23% and 21% of patients with Crohn's disease, respectively.<sup>24,25</sup> The cumulative frequency of perianal fistulas in one population-based study was 12% at 1 year, 15% at 5 years, 21% at 10 years, and 26% at 20 years (Figure 3).<sup>25</sup> Perianal fistulas occurred in 12% of patients with ileal Crohn's disease, 15% of patients with ileocolonic disease, 41% of patients with colonic disease with rectal sparing, and 92% of patients with colonic disease and rectal involvement.<sup>24</sup> Anal fissure or perianal fistula or abscess precedes or presents simultaneously with the diagnosis of intestinal disease in 36%–81% of patients with Crohn's disease

who develop perianal disease.<sup>14,21,24,25</sup> A small proportion of patients with Crohn's disease may persist in having only isolated perianal involvement.<sup>13,26</sup>

### Diagnosis

Modalities used to diagnose and classify Crohn's perianal fistulas include EUA, fistulography, computed tomography, pelvic MRI, and anorectal EUS.

### EUA

EUA consists of visual inspection, palpation, and the passage of malleable probes into fistula tracks under general anesthesia. EUA performed by an experienced colorectal surgeon has been considered the standard against which other diagnostic modalities are judged. However, recent studies comparing EUA with consensus diagnosis, pelvic MRI, or anorectal EUS have suggested that EUA is approximately 90% accurate in detecting and correctly classifying perianal fistulas, sinuses, and abscesses.<sup>27–33</sup> The accuracy of EUA may be enhanced by the use of intraoperative anorectal EUS with or without hydrogen peroxide contrast to enhance the sonographic identification of fistula tracks (see following text). In addition to diagnostic utility, EUA has the advantage of allowing concomitant surgical therapy such as incision and drainage of perianal abscess and placement of non-cutting setons, along with other advantages (see following text).

**Table 3.** 1992 Addition to the Hughes/Cardiff Classification (A.P.D.)

Associated anal conditions (A)	Proximal intestinal disease (P)	Disease activity (in anal locations) (D)
None-0	No proximal disease-0	Active-1
Hemorrhoids-1	Contiguous rectal disease-1	Inactive-2
Malignancy-2	Colon (rectum spared)-2	Inconclusive-3
Other (specify)-3	Small intestine-3	
	Investigation incomplete-4	

Modified and reprinted with permission from Hughes LE.<sup>7</sup>

**Table 4.** Types of Perianal Lesions in 202 Consecutive Patients in a Crohn's Disease Follow-up Clinic

Type of lesion	Number of patients (%)
Skin tag	75 (37)
Fissure	38 (19)
Low fistula	40 (20)
High fistula	12 (6)
Rectovaginal fistula	6 (3)
Perianal abscess	32 (16)
Ischiorectal abscess	8 (4)
Intersphincteric abscess	7 (3)
Supraleator abscess	6 (3)
Anorectal stricture	19 (9)
Hemorrhoids	15 (7)
Anal ulcer	12 (12)
Total patients with perianal lesions	110 (54)

From Keighley and Allan.<sup>12</sup>

### Fistulography and Computed Tomography

The diagnostic accuracy of older imaging modalities such as fistulography and computed tomography for the classification of fistula-in-ano and perianal Crohn's disease does not exceed 50%–60%, values that are generally considered too low to be clinically useful.<sup>34–45</sup>

### MRI

The techniques and findings of pelvic MRI examination of perianal Crohn's disease have been reviewed elsewhere.<sup>46,47</sup> Unlike fistulography and computed tomography, the diagnostic accuracy of pelvic MRI with phased-array or endoanal coils for classifying fistula-in-ano and perianal Crohn's fistulas ranges from 76% to 100%.<sup>27–33,48,49</sup> A number of studies have reported that pelvic MRI findings change surgical management in 10%–15% of cases.<sup>27–33</sup> The role of serial pelvic MRI examinations to follow the response of Crohn's perianal fistulas to medical therapies such as infliximab is unclear.<sup>50–52</sup>

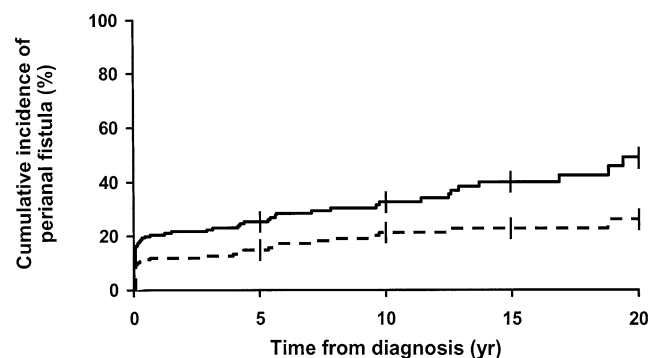
### Anorectal EUS

The diagnostic accuracy of endoanal ultrasonography ranges from 56% to 100%.<sup>32,39,53–58</sup> Also, similar to pelvic MRI, a number of studies have reported that anorectal EUS findings change surgical management in approximately 10%–15% of cases.<sup>32,57</sup> The role of serial anorectal EUS examinations to follow the response of Crohn's perianal fistulas to medical therapies such as infliximab is unclear.<sup>51,59,60</sup>

### Measurement of Fistula Disease Activity

The Crohn's Disease Activity Index score was developed to measure disease activity in patients whose

symptoms originate primarily from luminal disease.<sup>61</sup> Accordingly, patients whose symptoms originate primarily from perianal fistulas usually have low Crohn's Disease Activity Index scores.<sup>62</sup> Thus, the Crohn's Disease Activity Index is not suitable for measuring fistula activity.<sup>63</sup> Present et al. were the first to attempt measurement of fistula activity using a therapeutic goals score.<sup>64</sup> Patients were evaluated at baseline and assigned a baseline fistula activity score of 0. Fistula activity was then graded periodically using a 7-point scale that ranged from +3 to –3 based on fistula activity, with a positive number indicating improvement. This instrument is subjective and thus has not been widely used. In 1991, a working group suggested a functional classification for perianal Crohn's disease that included assessments of effect on essential activities such as sitting, defecating, and walking; effect on quality of life such as ability to work, enjoy life, sexual relationship, and sickness index profile; symptoms of incontinence; and need for medications such as narcotics and antibiotics.<sup>8</sup> This functional classification was never subsequently validated or used in clinical studies or clinical practice. The Perianal Disease Activity Index evaluates 5 categories affected by fistulas: discharge, pain, restriction of sexual activity, type of perianal disease, and degree of induration (Table 5).<sup>65</sup> Each category is graded on a 5-point Likert scale ranging from no symptoms (score of 0) to severe symptoms (score of 4). A higher score indicates more severe disease. The Perianal Disease Activity Index, which may in the future become the perianal disease equivalent of the Crohn's Disease Activity Index, has yet to be fully validated; in addition, the change in Perianal Disease Activity Index score that is clinically meaningful, as well as the absolute Perianal Disease Activity Index score equating with clinical remission of perianal fistulas, have not been determined. More recently, the Fistula Drainage Assessment



**Figure 3.** Cumulative incidence of perianal fistulas among 176 Olmsted County, Minnesota, residents diagnosed with Crohn's disease between 1970 and 1993. Modified and reprinted with permission from Schwartz et al.<sup>25</sup>

**Table 5.** Perianal Crohn's Disease Activity Index

Categories affected by fistulas	Score
Discharge	
No discharge	0
Minimal mucous discharge	1
Moderate mucous or purulent discharge	2
Substantial discharge	3
Gross fecal soiling	4
Pain/restriction of activities	
No activity restriction	0
Mild discomfort, no restriction	1
Moderate discomfort, some limitation activities	2
Marked discomfort, marked limitation	3
Severe pain, severe limitation	4
Restriction of sexual activity	
No restriction in sexual activity	0
Slight restriction in sexual activity	1
Moderate limitation in sexual activity	2
Marked limitation in sexual activity	3
Unable to engage in sexual activity	4
Type of perianal disease	
No perianal disease/skin tags	0
Anal fissure or mucosal tear	1
<3 Perianal fistulae	2
≥3 Perianal fistulae	3
Anal sphincter ulceration or fistulae with significant undermining of skin	4
Degree of induration	
No induration	0
Minimal induration	1
Moderate induration	2
Substantial induration	3
Gross fluctuance/abscess	4

From Irvine.<sup>65</sup>

has been used to classify fistulas as either open and actively draining or closed (Table 6).<sup>62</sup> A fistula is open and actively draining if the investigator can express purulent material from the fistula with the application of gentle pressure. The acute effects of therapy are assessed by determining if a patient has a fistula response (defined as closure of at least 50% of fistulas present at baseline maintained for at least 4 weeks) or has complete fistula closure (defined as closure of all fistulas present at baseline maintained for at least 4 weeks). The maintenance effects of therapy are assessed by determining the time to loss of fistula response or the time to loss of complete fistula closure. The terminology "closure of fistulas" probably does not accurately reflect the findings of EUA, pelvic MRI, or anorectal EUS, which often show persistent fistula tracts even when fistula drainage has ceased; thus, alternative terminology such as "cessation of drainage" should be considered. Although not addressed by the Fistula Drainage Assessment, it should be noted that it is important to reduce or eliminate anal pain in addition to fistula drainage.

## Medical Treatment

The pharmaceutical agents with definite or potential efficacy for treating patients with perianal Crohn's disease include antibiotics, azathioprine and 6-mercaptopurine, infliximab, cyclosporine, and tacrolimus.

### Antibiotics

There are no controlled trials showing that antibiotics are effective in the treatment of Crohn's perianal fistulas. The current clinical practice of using metronidazole or ciprofloxacin is based on uncontrolled case series and the absence of other therapeutic alternatives perceived to be safe for use in all patients.<sup>66-75</sup> A representative experience with metronidazole is that of Bernstein et al., who reported a series of 21 patients with perianal Crohn's disease treated with metronidazole 20 mg · kg<sup>-1</sup> · day<sup>-1</sup>.<sup>67</sup> All patients had a clinical response with a decrease in pain and tenderness. Ten of the 18 patients (56%) had complete healing of their perianal disease. Clinical improvement typically occurred after 6-8 weeks of therapy. A follow-up study of 17 of these patients, along with 9 additional patients, showed exacerbation of disease with dosage reduction as well as the occurrence of paresthesias in 13 of 26 patients (50%) (the paresthesias disappeared with dose reduction or drug discontinuation in 7 patients, paresthesias persisted under ongoing treatment in 5 patients, and hot/cold sensitivity persisted after drug discontinuation in 1 patient).<sup>68</sup> Clinicians prescribing antibiotics for fistulas typically use metronidazole at doses ranging from 750 to 1500 mg/day or ciprofloxacin 1000 mg/day for up to 3-4 months. Adverse events associated with metronidazole include metallic taste, glossitis, nausea, and a distal peripheral sensory neuropathy.<sup>76</sup> Adverse events associated with ciprofloxacin are uncommon but include headache, nausea, diarrhea, and rash.<sup>77</sup> A recent cost-utility study suggested that metronidazole combined with 6-mercaptopurine was a more cost-effective treatment

**Table 6.** Fistula Drainage Assessment

End point	Definition
Improvement	Closure of individual fistulas defined as no fistula drainage despite gentle finger compression. Improvement defined as a decrease from baseline in the number of open draining fistulas of ≥50% for at least 2 consecutive visits (i.e., at least 4 weeks).
Remission	Closure of individual fistulas defined as no fistula drainage despite gentle finger compression. Remission defined as closure of all fistulas that were draining at baseline for at least 2 consecutive visits (i.e., at least 4 weeks).

Modified and reprinted with permission from Present et al.<sup>62</sup>

strategy than infliximab-based treatment strategies (see following text).<sup>78</sup> However, this study may have underestimated the cost of patients with fistulas<sup>79</sup>; in addition, given that no controlled data support the efficacy of these agents, this conclusion is highly questionable.

### Azathioprine and 6-Mercaptopurine

There are no controlled trials with fistula closure as the primary end point showing that the antimetabolites azathioprine and 6-mercaptopurine are effective in the treatment of Crohn's perianal fistulas. The current clinical practice of using these medications is based on a meta-analysis of 5 controlled trials in which fistula closure was examined as a secondary end point<sup>80</sup> and uncontrolled case series in adults<sup>81</sup> and children.<sup>82</sup> The meta-analysis included 70 patients from 5 controlled trials of azathioprine or 6-mercaptopurine for Crohn's disease in which the details of fistula closure were described and could be used as a secondary end point (fistula closure was identified as a secondary end point post-hoc in 4 of the 5 studies specifically for the purposes of performing the meta-analysis).<sup>64,83-86</sup> The results of the meta-analysis showed that 22 of 41 patients (54%) treated with azathioprine or 6-mercaptopurine had fistula healing versus 6 of 29 patients (21%) treated with placebo, with a pooled odds ratio of 4.44 favoring healing of fistulas.<sup>80</sup> Clinical practice varies widely with respect to dosing and administration of azathioprine and 6-mercaptopurine. Controlled trials indicate that azathioprine at doses of 2.0–3.0 mg · kg<sup>-1</sup> · day<sup>-1</sup> and 6-mercaptopurine at a dose of 1.5 mg · kg<sup>-1</sup> · day<sup>-1</sup> is effective for the treatment of Crohn's disease. Some clinicians prefer to start either drug at a dose of 50 mg/day and gradually titrate to effect or to a "therapeutic" blood metabolite concentration to minimize the occurrence of adverse events, although the efficacy of this strategy is unproven. Adverse events associated with azathioprine and 6-mercaptopurine include leukopenia, allergic reactions, infection, pancreatitis, drug-induced hepatitis, and possibly non-Hodgkin's lymphoma.<sup>80,87,88</sup> Patients treated with these medications should have regular monitoring of leukocyte counts and liver transaminase levels.

### Infliximab

There are 2 controlled trials in which fistula closure was the primary end point showing that infliximab (a mouse/human chimeric monoclonal antibody to tumor necrosis factor) is effective in the treatment of Crohn's perianal fistulas.<sup>62,89</sup> Uncontrolled case series have also suggested that infliximab is of benefit for this indication.<sup>90-92</sup> In one placebo-controlled trial, 94 patients with draining Crohn's fistulas (85 patients had perianal

fistulas) were randomized to treatment with 3 infusions of placebo or infliximab at doses of 5 or 10 mg/kg at 0, 2, and 6 weeks.<sup>62</sup> Closure of at least 50% of fistulas was maintained for at least 4 weeks (primary study end point) in 26% of placebo-treated patients when compared with 68% of patients treated with infliximab 5 mg/kg and 56% of patients treated with infliximab 10 mg/kg ( $P = 0.002$  and  $P = 0.02$ , respectively). Closure of all fistulas was maintained for at least 4 weeks (secondary study end point) in 13% for placebo, 55% for infliximab 5 mg/kg, and 38% for infliximab 10 mg/kg ( $P = 0.001$  and  $P = 0.04$ , respectively). The median duration of closure was 3 months. Eleven percent of the patients treated with infliximab developed a perianal abscess, possibly due to closure of the cutaneous end of the fistula tract before the rest of the fistula tract closed. In a second controlled trial, 306 patients with actively draining fistulas received 3 doses of infliximab 5 mg/kg at 0, 2, and 6 weeks.<sup>89</sup> Patients who responded to therapy (closure of at least 50% of fistulas maintained for at least 4 weeks) were then randomized into 2 groups at week 14; group I received maintenance doses of placebo every 8 weeks beginning at week 14, and group II received maintenance doses of infliximab 5 mg/kg every 8 weeks beginning at week 14. The primary end point was "the time to loss of response" through week 54. A total of 195 of 306 patients (69%) had a fistula response at week 14. The median time to loss of response through week 54 was 14 weeks for placebo-treated patients and >40 weeks for patients treated with infliximab 5 mg/kg ( $P < 0.001$ ). At week 54, 39% of patients who received infliximab maintenance therapy had complete closure of all draining fistulas when compared with 19% of those who received placebo ( $P = 0.009$ ). Nevertheless, a recently reported observational study suggested that many patients treated with infliximab for fistulas will still require surgical intervention.<sup>93</sup> Another open study suggested that the combination of EUA and infliximab therapy for perianal fistulas led to more frequent and durable rates of healing.<sup>94</sup> Adverse events observed in patients treated with infliximab include infusion reactions, delayed hypersensitivity reactions, formation of human antichimeric antibodies, formation of antinuclear antibodies and anti-double-stranded DNA antibodies, and drug-induced lupus.<sup>95-97</sup> Concomitant immunosuppressive therapy with azathioprine, 6-mercaptopurine, or methotrexate is recommended to reduce the frequency of these reactions, which are largely due to an immunogenic response to the murine component of the chimeric antibody.<sup>98</sup> There is also an increased overall rate of infections and, rarely, serious infections including pneumonia, sepsis, tubercu-

losis, histoplasmosis, coccidioidomycosis, listeriosis, *Pneumocystis carinii* pneumonia, and aspergillosis occur.<sup>95-97,99-103</sup> It is recommended that patients undergo purified protein derivative skin testing before treatment with infliximab.<sup>97</sup>

### Cyclosporine

There are no controlled trials showing that cyclosporine is an effective therapy for Crohn's perianal fistulas. The current clinical practice of using intravenous cyclosporine is based on 10 uncontrolled case series that include a total of 64 patients.<sup>104-113</sup> The overall initial response rate in these studies was 83%. Cyclosporine was administered as a continuous intravenous infusion (because of poor oral bioavailability with older formulations) at a dose of  $4 \text{ mg} \cdot \text{kg}^{-1} \cdot \text{day}^{-1}$ . Clinical improvement occurred rapidly, typically within 7 days. Responding patients were converted to oral cyclosporine. Relapse rates were high when oral cyclosporine was discontinued.<sup>106,111,112,114</sup> Adverse events observed in patients treated with cyclosporine include renal insufficiency, hirsutism, hypertension, paresthesias, headache, seizure, tremor, gingival hyperplasia, hepatotoxicity, and an increased incidence of infection (including *P. carinii* pneumonia).<sup>114</sup>

### Tacrolimus

Uncontrolled case series have suggested that tacrolimus may be beneficial in the treatment of Crohn's perianal fistulas.<sup>115-118</sup> A single small placebo-controlled trial randomized 46 patients with actively draining Crohn's fistulas (43 patients had perianal fistulas) to treatment with placebo or oral tacrolimus at an initial dose of  $0.20 \text{ mg} \cdot \text{kg}^{-1} \cdot \text{day}^{-1}$ .<sup>119</sup> Closure of at least 50% of fistulas maintained for at least 4 weeks (primary study end point) occurred in 8% of placebo-treated patients when compared with 43% of patients treated with tacrolimus ( $P = 0.004$ ). Closure of all fistulas maintained for at least 4 weeks (secondary study end point) was 8% for placebo and 10% for tacrolimus ( $P = 0.86$ ). Adverse events observed in patients treated with tacrolimus include headache, increased serum creatinine level, insomnia, leg cramps, paresthesias, and tremor, typically resolved with dose reduction. The major toxicity observed in patients treated with tacrolimus was an increase in serum creatinine level from baseline to a value  $\geq 1.5 \text{ mg/dL}$  (designated before the study as nephrotoxicity requiring tacrolimus dose reduction), which occurred in 8 of 21 patients (38%) treated with tacrolimus compared with 0 of 25 (0%) placebo-treated patients ( $P = 0.008$ ).

### Other Miscellaneous Medical Therapies

There are no other controlled trials of other medical therapies for the treatment of Crohn's perianal fistulas. Uncontrolled case reports and case series have reported that a number of other medical therapies might be of benefit, including elemental diet, bowel rest with total parenteral nutrition, mycophenolate mofetil, methotrexate, thalidomide, granulocyte colony-stimulating factor, and hyperbaric oxygen.<sup>120-143</sup> Controlled trials are needed before these therapies can be recommended for routine use.

### Surgical Treatment

Early reports from referral centers have suggested that the clinical course of perianal Crohn's disease is relatively benign and that a low percentage of patients (approximately 10%–18%) require proctectomy, thus leading to the recommendation of a conservative approach with respect to surgery.<sup>144-146</sup> However, population-based natural history studies and more recent reports have suggested that the rates of recurrent disease and proctectomy are relatively high, suggesting a greater role for judicious surgical intervention.<sup>24,25,147,148</sup> Crohn's perianal disease lesions that are potential indications for surgical therapy include skin tags, hemorrhoids, anal fissures, anorectal strictures, perianal abscesses, perianal fistulas, rectovaginal fistulas, and cancer. Surgical therapies for Crohn's perianal disease include lateral sphincterotomy in selected patients with anal fissures, dilation of anorectal strictures, incision and drainage of perianal abscess, fistulotomy, placement of noncutting setons, transanal endorectal advancement flap, intestinal resection, temporary diverting colostomy or ileostomy, and proctectomy or proctocolectomy.<sup>149</sup> Obstetric surgical procedures involving the perineal area such as vaginal delivery and episiotomy must also be considered.

### Skin Tags

As noted in Table 1, 2 types of skin tags may occur: (1) typical Crohn's disease skin tags, which are large, edematous, hard, cyanotic, and often tender or painful, and (2) a variety of other skin tags including long (up to 2 cm) narrow polypoid lesions (fibroepithelial polyp) and large flat "elephant ear" tags, which are soft and painless. Although some investigators have advocated excisional biopsy of typical Crohn's disease skin tags to aid in the diagnosis,<sup>150</sup> the typical appearance and risk of postoperative complications, poor wound healing, and rare requisite for proctectomy preclude routine biopsy or excision.<sup>12</sup> On the other hand, the fibroepithelial

polypoid tags and elephant ear tags can be locally excised if clinically indicated in patients experiencing difficulty with perianal hygiene/toilet without concerns about wound healing (however, excision of these innocuous tags is rarely required).

### Hemorrhoids

Simple hemorrhoidectomy, the newer procedure for prolapsing hemorrhoids, and banding of hemorrhoids in patients with Crohn's disease are usually contraindicated due to the frequent occurrence of postoperative complications, including poor wound healing, anorectal stenosis, and a high rate of proctectomy,<sup>12,151,152</sup> notwithstanding one recent report suggesting that simple hemorrhoidectomy can be safely performed in selected patients.<sup>153</sup> When symptomatic prolapsing or bleeding hemorrhoids fail to respond to conservative measures, in the absence of active anorectal Crohn's disease, elastic band ligation may be used with great effect (Victor Fazio, unpublished experience, May 2003). It should also be noted that in patients without a preceding history/diagnosis of Crohn's disease who have a nonhealed hemorrhoidectomy wound 2–3 months postoperatively, investigation including colonoscopy is warranted to rule out occult Crohn's disease.

### Anal Fissures

Anal fissures in patients with Crohn's disease are usually painless<sup>6,15,144</sup> and spontaneously heal in more than 80% of patients.<sup>144,154</sup> Operative intervention in unselected patients does not improve the outcome and should generally be avoided.<sup>12</sup> However, in patients who have pain due to the fissure itself (not to local sepsis) and who do not have macroscopic evidence of rectal inflammation, lateral sphincterotomy may achieve healing without subsequent incontinence in most patients.<sup>153,155–157</sup> Fissurectomy is contraindicated. The role of topical glyceryl trinitrate, isosorbide dinitrate, diltiazem, botulinum toxin, and other pharmacologic agents that relax the anal sphincter to treat anal fissures in patients with Crohn's disease is unknown.

### Anorectal Strictures

Anal or rectal strictures may arise as complications of ulceration of the anal canal or rectum, perianal abscesses, and perianal fistulas and are often associated with ongoing rectal inflammation, complex perianal fistulas, and rectovaginal fistulas. Anal strictures may be short (<2 cm in length) and annular, resulting in a diaphragm-like deformity, or long and tubular. Symptoms are typically those of urgency, incontinence, tenesmus, frequency, and difficulty with defecation. Many

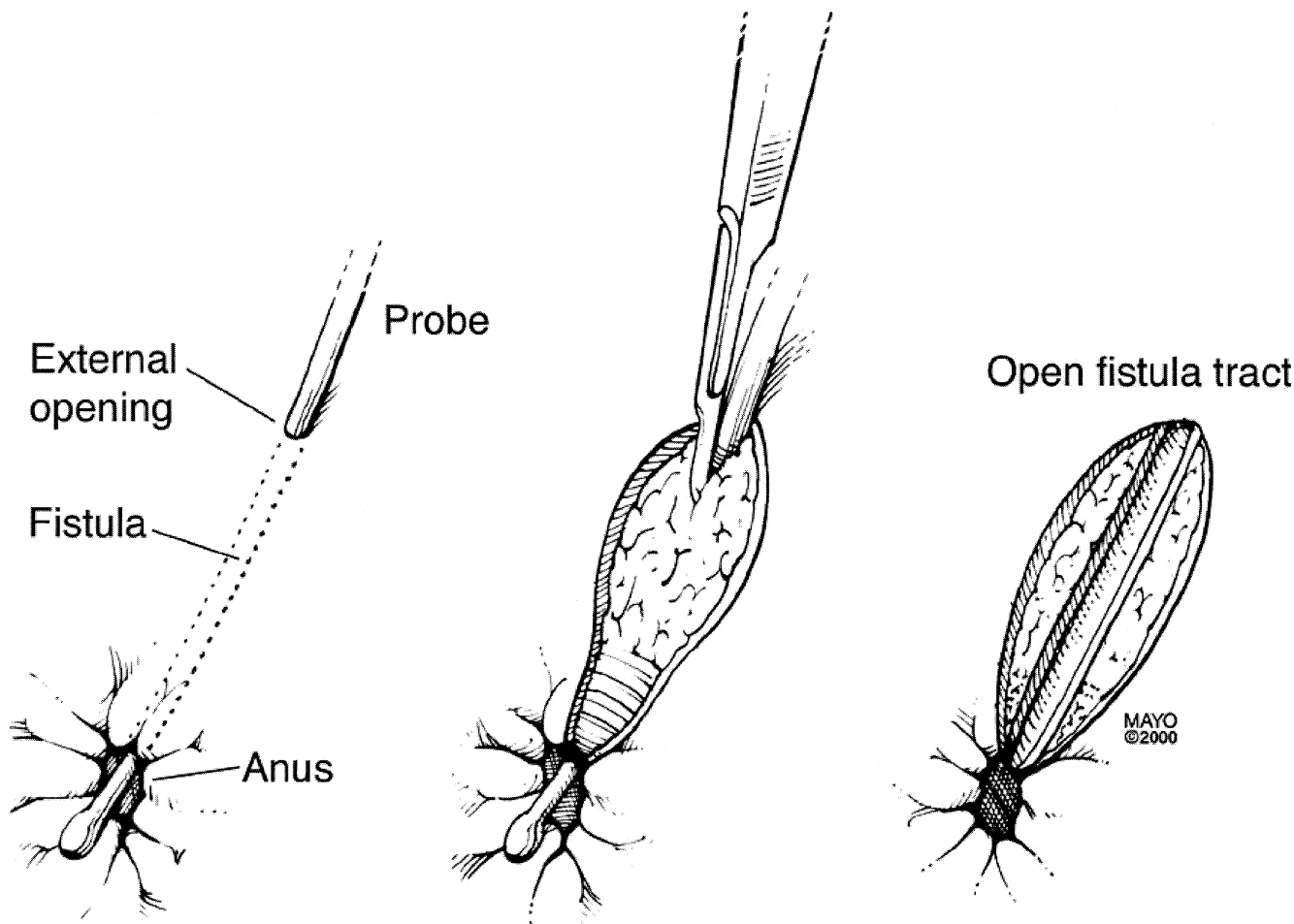
patients are asymptomatic and do not require treatment. For symptomatic patients, treatment consists of dilation with one-finger, Hegar's dilators not to exceed one finger's width, or coaxial balloons.<sup>12,158–161</sup> Repeat dilations are often required. Home dilators can be tried. Care must be taken to avoid overdilation with injury to the anal sphincter and incontinence. Some patients will require proctectomy.<sup>158,162</sup> There are no clinical trials or prospective outcome data to evaluate the efficacy or durability of dilation of anorectal strictures.

### Perianal Abscess

The presence of perianal pain, tenderness, or fluctuation in a patient with Crohn's disease suggests the possibility that a perianal abscess may have formed as a result of a cryptoglandular infection<sup>4</sup> or obstruction of a perianal fistula tract.<sup>163</sup> Perianal abscesses must be drained surgically.<sup>12,147,152,155,160,161,164–172</sup> A superficial perianal abscess can be defined as a subcutaneous perianal abscess near the skin surface, a perianal abscess close to the anal verge, an intersphincteric abscess with no cephalad extent above the dentate line, or an ischioanal abscess inferior to the postanal space (superficial to the anococcygeal ligament). Superficial perianal abscesses may be associated with a low perianal fistula and can be treated with incision and drainage. Fistulotomy of an associated low perianal fistula should not be performed in this setting because of the risk of poor wound healing (see following text). A deep perianal abscess can be defined as a perianal abscess at some distance from the skin surface, a deep postanal space abscess (i.e., ischioanal abscess bounded superiorly by the levator ani, inferiorly by the anococcygeal ligament and medial aspect of the external sphincter), or a supralelevator abscess (which may arise from an intersphincteric abscess or from extension of a transsphincteric abscess, or from an extrasphincteric origin such as a perforated rectum or ileal Crohn's disease perforation extending into the supralelevator space). Deep perianal abscesses may be associated with a high perianal fistula and should be treated with incision and drainage, followed by placement of a non-cutting seton if an associated high perianal fistula can be identified or placement of a mushroom catheter if an associated fistula cannot be identified. The placement of setons, while allowing prolonged drainage of the abscess, in essence perpetuates a perianal fistula.

### Perianal Fistulas

The surgical treatment of perianal fistulas in patients with Crohn's disease is determined by the presence or absence of macroscopic evidence of inflammation in the rectum and the type and location of the



**Figure 4.** In the absence of active proctocolitis, simple low transsphincteric, intersphincteric, and superficial fistulas can be treated with a fistulotomy. Reprinted with permission from Schwartz et al.<sup>149</sup>

fistula. Patients who have low fistulas (superficial, low intersphincteric, low transsphincteric) may be treated by laying open the fistula tract through 1- or 2-stage fistulotomy (Figure 4 and Table 7).<sup>12,18,19,21,152,155,160,165,167,168,170,171,173-180</sup> The initial healing rates in 21 studies of fistulotomy in patients with low fistulas ranged from 8% to 100%, with healing rates of 80%–100% in 13 of 21 studies, 60%–79% in 5 of 13 studies, and  $\leq 59\%$  in 3 of 21 studies (Table 7). The recurrence rates in 10 studies of patients with fistulotomy who initially healed ranged from 5% to 89%, with recurrence rates of 0%–20% in 7 of 10 studies, 21%–40% in 1 of 10 studies, and  $\geq 41\%$  in 2 of 10 studies (Table 7). The rates of incontinence following fistulotomy range from 0% to 50%, and the rates of proctectomy or long-term diverting stoma following fistulotomy range from 6% to 60% (Table 7). The wide range of rates of recurrence, incontinence, and proctectomy may reflect differences in patient selection and referral center bias, along with other differences. In general, there is a trend toward

greater healing rates following fistulotomy for low fistulas in patients without macroscopic evidence of inflammation of the rectum when compared with patients with active inflammation of the rectosigmoid colon; however, even in patients without macroscopic evidence of rectal inflammation, a nonhealing wound following fistulotomy for a low fistula will lead to proctectomy in some patients (Table 7). For this reason, many surgical experts advocate the use of a noncutting seton (see following text) rather than fistulotomy in patients with low fistulas and active inflammation of the rectosigmoid colon.

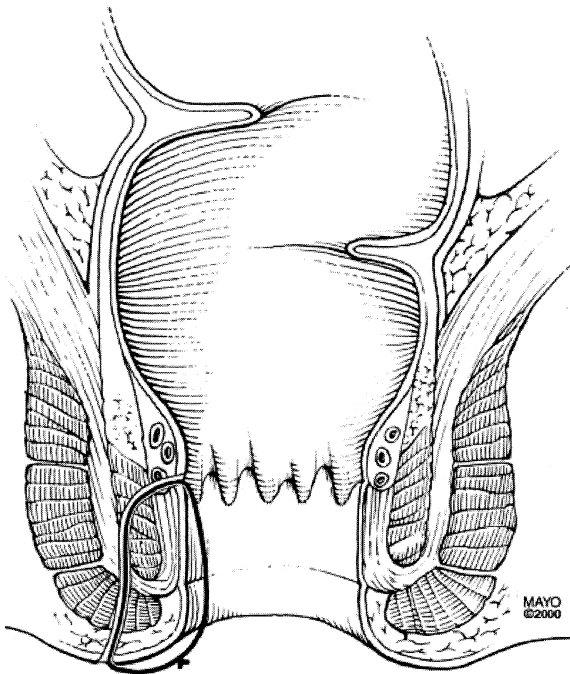
High fistulas involving a significant portion of the external anal sphincter (such as high intersphincteric, high transsphincteric, suprasphincteric, or extrasphincteric fistulas) require a more conservative surgical approach to reduce the risk of incontinence. Noncutting setons are the treatment of choice in patients with high fistulas who have active inflammation of the rectosigmoid colon and may also be used in patients with high fistulas who do not have macroscopic evidence of rectal

**Table 7.** Results of Conventional Fistulotomy by Laying Open the Tract for Low Perianal Fistulas in Patients With Crohn's Disease

Study	No. of patients	Healing (%)	Recurrence (%)	Incontinence (%)	Proctectomy (%)
Sohn et al. <sup>155a</sup>	4	4 (100)	0	0	0
Marks et al. <sup>18b</sup>	32	25 (78)	Not stated	Not stated	Not stated
Hobbiss et al. <sup>19a</sup>	20	18 (90)	4/18 (22)	Not stated	3 (15)
Keighley et al. <sup>12b</sup>	12	1 (8)	Not stated	6 (50)	Not stated
Bernard et al. <sup>160b</sup>	15	9 (60)	Not stated	Not stated	1 (7)
Fry et al. <sup>167b</sup>	13	13 (100)	Not stated	Not stated	0
Fuhrman et al. <sup>171b</sup>	19	18 (95)	Not stated	Not stated	2 (10)
Levien et al. <sup>165b</sup>	46	29 (63)	19 (41)	Not stated	4 (9)
Kangas <sup>168b</sup>	5	3 (60)	Not stated	Not stated	2 (40)
Williams et al. <sup>173b</sup>	33 (41 wounds)	38 wounds (93)	Not stated	7 patients (21)	3 patients (9)
Winter et al. <sup>174b</sup>	26	22 (85)	3/22 (14)	0	0
Williamson et al. <sup>170b</sup>	26	7 (27)	Not stated	Not stated	Not stated
Halme et al. <sup>175b</sup>	10	10 (100)	4 (40)	5 (50)	1 (10)
Scott et al. <sup>176b</sup>	27	22 (81)	Not stated	5 (19)	5 (19)—3 proctectomy + 2 stoma
McKee et al. <sup>177b</sup>	34	21 (62)	4/22 (18)	Not stated	10 (29)—7 proctectomy + 3 stoma
Sangwan et al. <sup>178b</sup>	35	35 (100)	31 (89)	0	0
Michelassi et al. <sup>179b</sup>	33	27 (82)	Not stated	Not stated	Not stated
Nordgren et al. <sup>21b</sup>	6 ileal or ileocecal	6 (100)	2 (33)	0	0
	5 proctocolitis	2 (40)	Not stated	0	3 (60)
Morrison et al. <sup>152b</sup>	17	16 (94)	2/16 (13)	Not stated	1 (6)
Platell et al. <sup>180b</sup>	44	40 (91)	2/40 (5)	0	0

<sup>a</sup>Absence of active proctocolitis in all patients with low perianal fistulas.

<sup>b</sup>Presence of active proctocolitis in some patients with low perianal fistulas.



**Figure 5.** A noncutting seton is a suture or drain that is threaded into the cutaneous orifice of a perianal fistula, through the fistula tract, across the mucosal orifice of the fistula into the rectum, and through the rectum across the anus where the 2 ends of the suture or drain are loosely tied. Reprinted with permission from Schwartz et al.<sup>149</sup>

inflammation (Figure 5 and Table 8).<sup>20,152,164,170,172,173,175–178,181–184</sup> A noncutting seton is a suture or drain that is threaded into the cutaneous orifice of a perianal fistula, through the fistula tract, and across the mucosal orifice of the fistula into the rectum and then out the anal canal (Figure 5). A noncutting seton maintains drainage of the fistula, thereby reducing the risk of perianal abscess formation. Fistulas reoccur frequently following the removal of noncutting setons (Table 8). Fistulotomy or fistula excision (fistulectomy) in patients with high fistulas has been associated with a high rate of subsequent proctectomy due to nonhealing or incontinence (Table 8).<sup>21,152,175,177,185</sup> A cutting seton is formed by tying a noncutting seton tightly, causing pressure necrosis that essentially results in a slow fistulotomy that can also result in both nonhealing and incontinence.

An endorectal advancement flap can be used as an alternative to fistulotomy in patients with low fistulas who do not have macroscopic evidence of rectal inflammation and similarly as an alternative to noncutting setons in patients with high fistulas who do not have macroscopic evidence of rectal inflammation (Table 8).<sup>167,170,177,186–191</sup> An advancement flap consists of incising a flap of tissue (mucosa, submucosa, circular muscle) around the internal opening of a fistula, excising the internal opening of the fistula tract, and pulling the flap down to cover the opening (Figure 6).<sup>189</sup> A refinement of

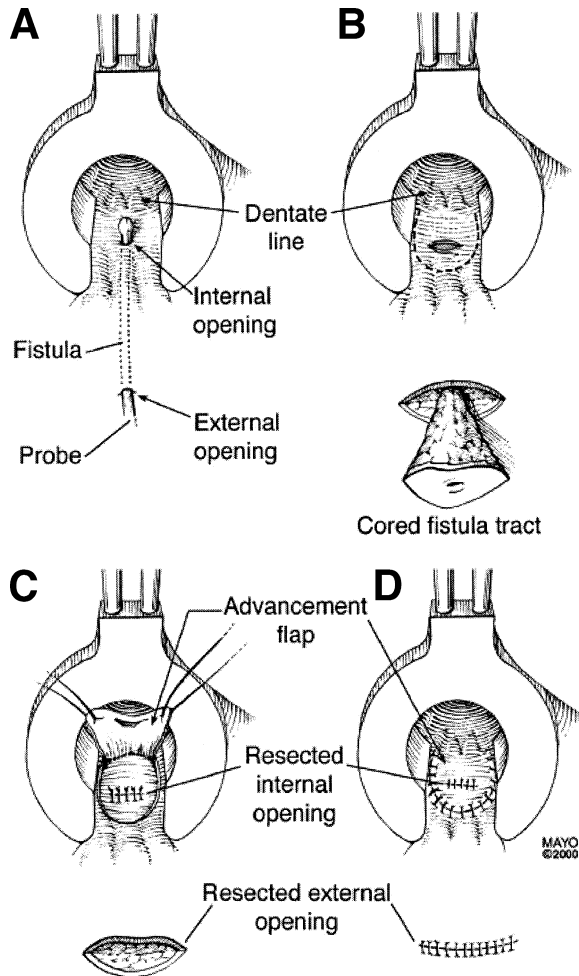
**Table 8.** Results of Treatment of High or Complex Perianal Fistulas in Patients With Crohn's Disease

Study	No. of patients	Treatment	Healed (%)	Recurrence (%)	Incontinence (%)	Proctectomy (%)
van Dongen et al. <sup>20</sup>	2	Seton	2 (100)	0	Not stated	0
Williams et al. <sup>173</sup>	22	Seton	19/22 (86)	9/19 (47)	14 (66)	3 (14)
Sangwan et al. <sup>178</sup>	24	Seton	22/24 (92)	17/24 (63)	Not stated	7 (33)
Scott et al. <sup>176</sup>	27	Seton	23/27 (85)	4/27 (15)	4 (15)	4 (15)
White et al. <sup>164</sup>	10	Seton	10/10 (100)	2/10 (20)	Not stated	0
Koganei et al. <sup>172</sup>	13	Seton	10/13 (77) improved 0 closed	3/10 (30)	0	1 (8)
Sugita et al. <sup>181</sup>	21	Seton	17/21 (81) improved 8 (38) closed	9/17 (53)	1 (5)	Not stated
Williams et al. <sup>182</sup>	23	Seton	20/23 (87) improved 3/23 (13) closed	9/20 (45)	6 (26)	5 (22)
Faucheron et al. <sup>183</sup>	41	Seton	36/41 (88) improved 11/41 (27) closed	8/36 (22)	5 (12)	5 (12)
Pearl et al. <sup>184</sup>	21	Seton	21/21 (100)	0	0	0
Williamson et al. <sup>170</sup>	9	Seton	7/9 (78)	2/9 (22)	Not stated	Not stated
McKee et al. <sup>177</sup>	7	Seton	4/7 (57)	3/7 (43)	Not stated	2 (29)
Halme et al. <sup>175</sup>	5	Seton or excision + fecal diversion	1 (20)	Not stated	Not stated	3 (60)
Morrison et al. <sup>152</sup>	2	Seton + lay open	2/2 (100)	Not stated	Not stated	0
Morrison et al. <sup>152</sup>	2	Lay open	2/2 (100)	Not stated	Not stated	0
McKee et al. <sup>177</sup>	5	Lay open	2/5 (40)	3/5 (60)	2 (40)	2 (40)
Halme et al. <sup>175</sup>	1	Lay open	0	0	Not stated	0
Nordgren et al. <sup>21</sup>	10	Lay open	4/10 (40)	1/4 (25)	Not stated	6 (60)
Morrison et al. <sup>152</sup>	2	Lay open and/or excision + fecal diversion	1/2 (50)	Not stated	Not stated	1 (50)
Matos et al. <sup>185</sup>	10	Excision and primary closure	10/10 (100)	6 (60)	5/10 (50)	0
Jones et al. <sup>186</sup>	6	Transanal full-thickness advancement flap	2/6 (33)	4/6 (67)	Not stated	1 (17)
Fry et al. <sup>167</sup>	3	Transanal advancement flap	3/3 (100)	0	Not stated	0
Lewis et al. <sup>187</sup>	6	Transanal full-thickness advancement flap	5/6 (83)	1/6 (17)	Not stated	0
Makowiec et al. <sup>188</sup>	20	Transanal advancement flap	16/20 (80)	4/20 (20)	0	0
Joo et al. <sup>189</sup>	26	Transanal advancement flap	19/26 (73)	7/26 (27)	Not stated	2 (9)
Robertson et al. <sup>190</sup>	6	Transanal advancement flap	3/6 (50)	3/6 (50)	Not stated	0
Williamson et al. <sup>170</sup>	4	Transanal advancement flap	1/4 (25)	3/4 (75)	Not stated	Not stated
McKee et al. <sup>177</sup>	2	Transanal advancement flap	1/2 (50)	1/2 (50)	Not stated	1 (50)
Marchesa et al. <sup>191</sup>	13	Sleeve advancement flap	8/13 (62)	5/13 (38)	Not stated	3 (23)

the technique has been used when the anal canal is ulcerated or recently affected with an active disease and where the rectum appears endoscopically normal. The advancement rectal sleeve procedure involves circumferential excision, lifting the anal canal mucosa from the dentate line to the anorectal ring, mobilization of a full-thickness rectal flap (as done in the Altemeir procedure for rectal prolapse), and anastomosis of the rectal sleeve to the dentate line.<sup>191</sup> Success rates in this highly selected group of patients have been 65%.

Placement of a temporary diverting ileostomy or colostomy has been used to treat severe perianal Crohn's

disease. The rationale for fecal diversion is to reduce fecal flow across the fistula tract by reducing flow through the rectum, allowing the rectal mucosa to heal and the fistula to close. Fecal diversion procedures are now only rarely performed as a primary therapy after a number of studies showed that patients who undergo placement of a temporary diverting ileostomy or colostomy for perianal Crohn's disease almost never have intestinal continuity restored.<sup>192-197</sup> A second rationale for diverting ileostomy is that significant perianal sepsis poses a major risk for an unhealed perianal wound when proctectomy or proctocolectomy is required. Subsidence of active sepsis



**Figure 6.** Endorectal advancement flap. (A) Probe the fistula tract to identify the internal opening of the fistula. (B) Incise the internal opening of the fistula tract. (C) Incise a flap of tissue (includes mucosa, submucosa, and circular muscle) around the site of the resected internal opening of the fistula. (D) Pull the flap down to cover the site of the resected internal opening of the fistula. Reprinted with permission from Schwartz et al.<sup>149</sup>

by preliminary fecal diversion may lessen the risk of the unhealed perianal wound at the time of definitive resection. Historically, the proctectomy rate for perianal Crohn's disease in conservatively managed patients ranges from 10% to 18%.<sup>146,165,173</sup> Whether the more frequent use of noncutting setons and treatment with infliximab has reduced the frequency of proctectomy has not yet been determined.

### Rectovaginal Fistulas

Surgical treatment of rectovaginal fistulas in patients with perianal Crohn's disease should only be attempted in the absence of active inflammation of the rectosigmoid colon. Although there are reports of patients with low fistulas (superficial, low intersphincteric, low transsphincteric) being treated by laying open the

fistula tract through conventional fistulotomy (Table 9),<sup>9,173,198–203</sup> this procedure should rarely, if ever, be used in patients with rectovaginal fistulas; anterior fistulotomy in this setting is considered very hazardous due to sphincter injury risk. Patients with rectovaginal fistulas may be treated by a number of other approaches, including primary closure,<sup>198,200–206</sup> transanal advancement flap,<sup>167,179,186,188,202,203,205,207–210</sup> sleeve advancement flap,<sup>209–211</sup> and transvaginal advancement flap.<sup>203,212,223</sup> (Table 9). Although there are reports of patients with rectovaginal fistulas being treated with placement of a noncutting seton (Table 9),<sup>179</sup> this procedure should rarely, if ever, be used in patients with rectovaginal fistulas; placement of noncutting setons in this setting tends to enlarge the opening, making the fistula more symptomatic. An exception is when there is a rectovaginal septal abscess or inflammatory mass in addition to the fistulas. In this circumstance, drainage of the inflamed septum may be enhanced by a noncutting seton. In general, the success rates for primary closure and advancement flaps in patients with rectovaginal fistulas range from approximately 50% to 100%.

### Obstetric Surgical Procedures (Vaginal Delivery and Episiotomy)

One study suggested that vaginal delivery led to an exacerbation of perianal disease in patients with a history of perianal disease independent of the activity of the perianal disease at the time of delivery,<sup>213</sup> whereas another study suggested that worsening of perianal disease was limited to those women with active perianal disease at the time of vaginal delivery.<sup>214</sup> Based on these data, it is recommended that pregnant female patients with active perianal Crohn's disease at the time of delivery undergo cesarean section, whereas patients with no history of perianal disease and those with inactive perianal disease can undergo vaginal delivery in the absence of other indications for cesarean section.

### Cancer

Case reports and case series have identified patients with Crohn's perianal disease in whom squamous cell carcinoma, basal cell carcinoma, and adenocarcinoma have developed in chronic perianal fistula or sinus tracts.<sup>215–221</sup> The possibility of malignancy should always be considered when examining nonhealing fistulas, and curettage or biopsy of the fistulous tract and histologic review of the curetted or biopsy material should be performed when cancer is suspected or when risk factors for cancer (e.g., longstanding fistulas) are present. When cancer is identified in a fistula track, standard oncologic surgical principles and procedures should be followed.

**Table 9.** Results of Surgical Treatment of Rectovaginal Fistulas in Patients With Crohn's Disease

Study	No. of patients	Type of repair	Healed (%)	Proctectomy (%)
Francois et al. <sup>9</sup>	9	Lay open	9 (100)	0
Hudson <sup>198</sup>	5	Lay open	3 (60)	0
Faulconer et al. <sup>199</sup>	3	Lay open	0	2 (67)
Givel et al. <sup>200</sup>	1	Lay open	0	0
Bandy et al. <sup>201</sup>	1	Lay open	1 (100)	0
Radcliffe et al. <sup>202</sup>	12	Lay open	6 (50)	4 (33)
Williams et al. <sup>173</sup>	1	Lay open	0	1 (100)
O'Leary et al. <sup>203</sup>	1	Lay open	1 (100)	0
Hudson <sup>198</sup>	4	Primary closure	3 (75)	0
Tuxen et al. <sup>204</sup>	2	Primary closure	1 (50)	0
Givel et al. <sup>200</sup>	2	Primary closure	1 (50)	0
Bandy et al. <sup>201</sup>	9	Primary closure	8 (89)	0
Cohen et al. <sup>205</sup>	6	Primary closure	3 (50)	1 + 1 ileostomy (33)
O'Leary et al. <sup>203</sup>	2	Primary closure	1 (50)	0
Wiskind et al. <sup>206</sup>	3	Primary closure	3 (100)	0
Radcliffe et al. <sup>202</sup>	4	Primary closure	2 (50)	3/15 (20) <sup>a</sup>
	5	Anterior advancement flap	3 (60)	<sup>a</sup>
	6	Transanal advancement flap	4 (67)	<sup>a</sup>
Farkas et al. <sup>207</sup>	1	Transanal advancement flap	1 (100)	0
Jones et al. <sup>186</sup>	10	Transanal full-thickness advancement flap	6 (60)	1 (10)
Fry et al. <sup>167</sup>	3	Transanal endorectal mucosal flap	2 (67)	0
Cohen et al. <sup>205</sup>	1	Transanal advancement flap	0	0
Hesterberg et al. <sup>208</sup>	10	Transanal anocutaneous flap	7 (70)	0
Makowiec et al. <sup>188</sup>	12	Transanal advancement flap	10 (83)	0
Hull et al. <sup>209,210</sup>	24	Curvilinear advancement flap	13 (54)	3 (13)
	6	Linear advancement flap	3 (50)	1 (17)
O'Leary et al. <sup>203</sup>	6	Transanal advancement flap	3 (50)	0
Michelassi et al. <sup>179</sup>	16	Transanal advancement flap	4 (25)	11 (69)
Hull et al. <sup>209,210</sup>	5	Sleeve advancement flap	3 (60)	1 (20)
Simmang et al. <sup>211</sup>	2	Sleeve advancement	2 (100)	0
Sher et al. <sup>212,223</sup>	14	Transvaginal flap	13 (93)	1 ileostomy (7)
O'Leary et al. <sup>203</sup>	1	Transvaginal flap	0	0
Michelassi et al. <sup>179</sup>	1	Seton	0	0

<sup>a</sup>Details regarding rates of proctectomy for 3 types of repair not provided.

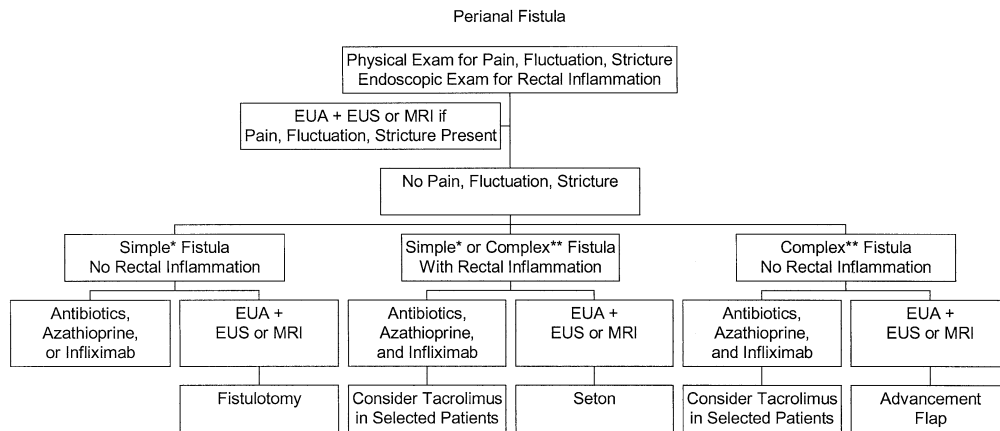
## Approach to Treatment

The treatment of perianal fistulas in patients with Crohn's disease should be approached with knowledge of the relevant perianal anatomy, diagnostic modalities, and medical and surgical treatment options. The therapeutic plan devised for each patient must take into account the activity of the proximal luminal Crohn's disease and, in particular, disease activity in the rectum, the location and type of fistulas present, and the severity of the patient's symptoms.

## Diagnosis

To plan appropriate medical or surgical therapy, patients with perianal Crohn's disease are classified as having simple fistulas or complex perianal disease. As previously described, simple fistulas are low, have a single external opening, and do not have associated perianal abscess, rectovaginal fistula, anorectal stricture, or macroscopically evident rectal inflammation; complex fistulas are high and/or have multiple external openings, perianal abscess, rectovaginal fistula, anorectal stricture,

or macroscopic evidence of rectal inflammation. Diagnosis of simple fistulas or complex perianal disease by physical examination and rectosigmoid endoscopy may be sufficient for many patients when medical therapy is the initial treatment strategy (Figure 7), although one preliminary report suggests that EUA before medical therapy with infliximab led to more frequent and durable rates of clinical response by identifying perianal abscesses that were not suspected based on physical examination.<sup>94</sup> Additional diagnostic evaluation by EUA and either anorectal EUS or pelvic MRI is indicated in those patients with pain, fluctuation, or stricture on digital rectal examination and in those patients in whom surgical therapy is the initial treatment strategy, because up to 10% of patients with perianal fistulas will be misclassified by EUA alone (Figure 7).<sup>27-33</sup> In addition, fistulotomy of a high fistula misclassified as a low fistula may lead to incontinence and/or poor wound healing and in some instances subsequent proctectomy. It is recognized that this recommendation represents a change in practice, even for gastroenterologists and colorectal surgeons



**Figure 7.** Treatment algorithm for managing patients with Crohn's perianal fistulas. EUA, anorectal EUS; MRI, pelvic MRI. A simple fistula (\*) is low, has a single external opening, and does not have associated perianal abscess, rectovaginal fistula, anorectal stricture, or macroscopically evident rectal inflammation. A complex fistula (\*\*) is high and/or has multiple external openings, perianal abscess, rectovaginal fistula, anorectal stricture, or macroscopic evidence of rectal inflammation.

with great expertise in the management of perianal Crohn's disease, but acknowledges that EUA is not 100% accurate and that inaccurate diagnosis before surgical intervention may lead to irreversible functional consequences. In addition, EUA and either anorectal EUS or pelvic MRI should be considered in all patients with a simple fistula or complex perianal disease who fail medical or surgical therapy to identify remediable causes of treatment failure.

### General Treatment of Crohn's Disease

In addition to the specific medical and surgical treatments outlined as follows, any active proximal luminal disease should also be treated as appropriate with budesonide, conventional corticosteroids, azathioprine, 6-mercaptopurine, methotrexate, infliximab, and surgical resection.<sup>222</sup> Postoperative bile salt diarrhea or steatorrhea should be treated as indicated with loperamide, diphenoxylate and atropine, codeine, cholestyramine, and low-fat diet.<sup>222</sup> These measures are all aimed at reducing stool liquidity, with the goal of decreasing the quantity of fistula drainage, thus optimizing the opportunity for the fistula to close.

### Specific Treatment of Simple Perianal Fistulas

The treatment goal for patients with simple fistulas should be cure, ideally without the requirement for long-term maintenance therapy that is administered primarily to suppress recurrence of the fistula. Potential treatments for simple fistulas include antibiotics, fistulotomy, and possibly azathioprine or 6-mercaptopurine and infliximab (Figure 7). Antibiotics are widely used to treat simple fistulas and are recommended in practice guidelines and previous treatment algorithms<sup>149,222</sup> but have not been evaluated in placebo-controlled trials. Fistulotomy is widely used by surgeons to treat simple fistulas, and this procedure results in a high rate of

healing that is often sustained. The prevailing view among surgeons is that those patients with a simple fistula who do not respond to a short course of antibiotics are best treated with fistulotomy. However, reported surgical series have been small, there are no controlled trials comparing fistulotomy with sham operation or medical therapy, and some patients fail to heal and may require proctectomy. The immunosuppressive medications azathioprine and 6-mercaptopurine can be used to treat simple fistulas and are recommended in practice guidelines<sup>222</sup> but have not been evaluated in placebo-controlled trials in which fistula reduction or closure was the primary end point. Many experts believe that the rate of response in patients in whom the indication for treatment is draining fistulas is lower than in those patients with other treatment indications. Furthermore, these agents are slow acting and thus may be of more utility for maintaining fistula closure than for the initial induction of fistula closure. Infliximab has been proven effective in placebo-controlled trials for the indications of both reduction in the number of draining fistulas and maintenance of that reduction, and a 3-dose induction regimen as well as an every 8-week maintenance regimen are approved by the U.S. Food and Drug Administration for treatment of fistulas; however, infliximab is expensive, concomitant immunosuppressive therapy is probably required to counteract the formation of human antichimeric antibodies that may lead to infusion reactions and loss of efficacy, and rarely serious infections may occur. There are insufficient high-quality data (level 1 evidence) to make a clear recommendation as to whether antibiotics, fistulotomy, azathioprine or 6-mercaptopurine, or infliximab is the preferred strategy for simple fistulas. It is possible that "curative" fistulotomy may have a lower economic cost than induction and maintenance therapy with infliximab, but caution should be used in accepting this conclusion because there are insufficient prospec-

tively collected data detailing the morbidity (rates of incontinence and proctectomy) following fistulotomy. Additionally, there are insufficient data to determine whether long-term maintenance therapy with infliximab is required in patients with simple fistulas who respond to induction therapy. Tacrolimus and cyclosporine are not appropriate treatment for simple fistulas because of toxicity.

### Specific Treatment of Complex Perianal Fistulas

The treatment goal for patients with complex fistulas is typically fistula closure and then suppression of recurrence. Potential treatments for complex fistulas include antibiotics, azathioprine and 6-mercaptopurine, infliximab, and surgery (dilation of anal strictures, placement of noncutting setons, endorectal advancement flap, repair of rectovaginal fistulas, fecal diversion, and proctectomy) (Figure 7). Tacrolimus and cyclosporine may rarely be used in selected patients. Antibiotics are widely used to treat complex fistulas and are recommended in practice guidelines and treatment algorithms<sup>149,222</sup> but have not been evaluated in placebo-controlled trials. Relapse rates for complex fistulas are high after antibiotic therapy is discontinued, and their use should probably be adjunctive in combination with other medical agents or surgery in this setting. Similarly, the immunosuppressive medications azathioprine and 6-mercaptopurine have been used to treat complex fistulas and are recommended in practice guidelines<sup>222</sup> but have not been evaluated in placebo-controlled trials for fistula closure. These agents are slow acting and thus are of more utility for maintaining fistula closure than for the initial induction of fistula closure. In contrast to antibiotics and immunosuppressive medications, infliximab has been proven to be effective in placebo-controlled trials for reduction in the number of draining fistulas and maintenance of that reduction, and treatment of fistulas with a 3-dose induction regimen and an every 8-week maintenance regimen of infliximab is approved by the Food and Drug Administration; although therapy with infliximab is expensive and concomitant immunosuppressive therapy is probably required, these factors are of less consequence in patients with complex perianal fistulas who have an otherwise poor prognosis. Surgical therapy for complex perianal disease is largely palliative. Perianal abscesses should be drained and anal strictures dilated. Noncutting setons can be placed in fistula tracts in patients with macroscopic rectal inflammation, and endorectal advancement flap procedures for high perianal fistulas and rectovaginal fistulas can be performed in patients without rectal inflammation. However, the re-

currence rates following removal of noncutting setons and following endorectal advancement flap procedures are both relatively high. Setons can be left in place indefinitely; however, given the alternative of suppressive medical therapy, patients may not prefer this option. Fistulotomy and cutting setons are relatively contraindicated due to risk of nonhealing and incontinence. Because infliximab therapy can completely close all fistula tracks in many patients with complex fistulas, most gastroenterologists now believe that infliximab is the initial treatment of choice in this setting (it is debated by surgeons whether infliximab or noncutting setons is the initial treatment of choice for the subgroup of patients with complex perianal fistulas who do not have active rectal disease, because there are no data on patient acceptance of long-term noncutting setons versus treatment with infliximab). In patients treated with infliximab, azathioprine, 6-mercaptopurine, or methotrexate should be initiated before or coadministered routinely both to counteract an immunogenic reaction to infliximab and as maintenance of remission therapy. Many patients will require combination maintenance therapy with azathioprine, 6-mercaptopurine, or methotrexate and infliximab. Temporary adjunctive therapy with antibiotics may be considered. It is clear from clinical trials with infliximab that routine EUA and seton placement before initiating infliximab therapy is not mandatory. Whether or not the outcome with infliximab therapy for complex fistulas is improved through a multimodality approach that includes both temporary placement of setons and therapy with infliximab, azathioprine or 6-mercaptopurine, and an antibiotic is unknown. The rationale for such an approach is that the temporary placement of setons guarantees resolution of sepsis (which can be a reason for infliximab failure); the setons are removed after 1 or 2 doses of infliximab to allow the fistulas to close. Patients with complex fistulas who initially fail treatment with infliximab should undergo anorectal EUS or pelvic MRI as well as EUA with placement of setons as indicated while continuing treatment with infliximab, azathioprine or 6-mercaptopurine, and antibiotics. Tacrolimus or cyclosporine can rarely be considered in selected patients who fail multimodality treatment with other medical and surgical therapies, including infliximab.<sup>222</sup> This practice is based on uncontrolled case series with cyclosporine and a single short-term placebo-controlled trial with tacrolimus that showed a reduction in the number of draining fistulas; however, nephrotoxicity and other side effects occur frequently and should be used with caution. In addition, the trials examining tacrolimus and cyclosporine have

been of short duration, without determining whether maintenance therapy after initial fistula closure is safe and effective. As a last resort, fecal diversion or proctectomy may be undertaken.

### Specific Treatment of Rectovaginal Fistulas

The treatment goals for patients with rectovaginal fistulas are initially to decrease fistula drainage to a minimal level that is "acceptable" or ideally to completely close the fistula, then suppression of recurrence, and then cure if possible. Potential treatments for rectovaginal fistulas include both medical therapy and surgery. 6-Mercaptopurine, infliximab, cyclosporine, and tacrolimus have all been used to treat rectovaginal fistulas in uncontrolled series.<sup>81,90,106,107,112,117</sup> A recent controlled trial of maintenance infliximab infusions in patients with fistulas who responded to infliximab included a subgroup of patients with rectovaginal fistulas.<sup>89</sup> In general, the rates of closure for rectovaginal fistulas appear to be lower than for perianal fistulas. Surgical treatment of rectovaginal fistulas can only be performed when there is endoscopic healing of the rectosigmoid mucosa. Thus, standard medical therapy with conventional corticosteroids, azathioprine, 6-mercaptopurine, methotrexate, and infliximab should be administered as indicated to control active luminal inflammatory disease in the rectosigmoid colon.<sup>222</sup> Other perianal disease should be treated as previously outlined. If the rectovaginal fistula persists after the patient has received medical therapy to treat both the fistula itself and the rectosigmoid mucosa and there is no evidence of an anorectal stricture or active rectal disease, then surgical repair with transanal or transvaginal advancement flaps, or laparotomy with primary closure or sleeve advancement flap, can be performed. Temporary diverting ileostomy or colostomy may be performed simultaneously in selected cases. If the advancement flap procedures (which involve coring out the fistula) fail, the rectovaginal fistula may actually increase in size and result in a worsening of symptoms. Thus, advancement flap surgery should be reserved for patients with disabling symptoms (by their definition), that is, stool per vagina, recurrent vaginitis, and vulvar excoriation. As a last resort, fecal diversion or proctectomy may be undertaken. Some women in whom rectovaginal fistula drainage has diminished but not stopped following medical and/or surgical therapy may choose to accept residual fistula drainage over proctectomy with an ostomy to optimize their overall quality of life.

### Conclusions

Perianal disease occurs frequently in patients with Crohn's disease. Diagnostic evaluation with physical examination and rectosigmoid endoscopy, supplemented in some cases with EUA and anorectal ultrasonography or pelvic MRI, is required to determine the location and type of fistulas and the presence or absence of macroscopic rectal inflammation. Skin tags and hemorrhoids should not be operated on. Most anal fissures should not be operated on. Lateral sphincterotomy can be considered in selected cases. Anorectal strictures should be dilated and perianal abscesses drained. Simple fistulas can be treated with antibiotics, infliximab, or fistulotomy. The treatment goal is cure without suppressive maintenance therapy. Complex perianal disease should be treated initially with infliximab and azathioprine or 6-mercaptopurine, followed by maintenance therapy with azathioprine or 6-mercaptopurine, in some cases combined with infliximab. Antibiotics may be used as adjunctive therapy during the induction phase of treatment. EUA and placement of noncutting setons or performing endorectal advancement flap procedures is reserved for patients who fail a trial of medical therapy. Tacrolimus or cyclosporine can rarely be considered in selected patients who fail multimodality treatment with other medical and surgical therapies, including infliximab, before proceeding to fecal diversion or proctectomy.

WILLIAM J. SANDBORN

*Mayo Clinic  
Rochester, Minnesota*

VICTOR W. FAZIO

*Cleveland Clinic  
Cleveland, Ohio*

BRIAN G. FEAGAN

*University of Western Ontario  
London, Ontario, Canada*

STEPHEN B. HANAUER

*University of Chicago  
Chicago, Illinois*

### References

1. Goligher J. Fistula-in-ano. In: Goligher J, ed. *Surgery of the anus, rectum, and colon*. 5th ed. Bailliere Tindall, 1984;178-220.
2. Parks A. The pathogenesis and treatment of fistula-in-ano. *BMJ* 1961;1:463-1469.
3. Milligan ET, Morgan CN. Surgical anatomy of the anal canal with special reference to anorectal fistulae. *Lancet* 1934;2:1213.
4. Parks AG, Gordon PH, Hardcastle JD. A classification of fistula-in-ano. *Br J Surg* 1976;63:1-12.
5. Buchmann P, Alexander-Williams J. Classification of perianal Crohn's disease. *Clin Gastroenterol* 1980;9:323-330.

6. Hughes LE. Surgical pathology and management of anorectal Crohn's disease. *J R Soc Med* 1978;71:644-651.
7. Hughes LE. Clinical classification of perianal Crohn's disease. *Dis Colon Rectum* 1992;35:928-932.
8. Alexander-Williams J, Hellers G, Hughes LE, Minervini S, Speranza V. Classification of perianal Crohn's disease. *Gastroenterol Int* 1992;5:216-220.
9. Francois Y, Vignal J, Descos L. Outcome of perianal fistulae in Crohn's disease—value of Hughes' pathogenic classification. *Int J Colorectal Dis* 1993;8:39-41.
10. Pikarsky AJ, Gervaz P, Wexner SD. Perianal Crohn disease: a new scoring system to evaluate and predict outcome of surgical intervention. *Arch Surg* 2002;137:774-777; discussion 778.
11. Bell SJ, Williams AB, Wiesel P, Wilkinson K, Cohen RCG, Kamm MA. The clinical course of fistulating Crohn's disease. *Aliment Pharmacol Ther* 2003;17:1145-1151.
12. Keighley MR, Allan RN. Current status and influence of operation on perianal Crohn's disease. *Int J Colorectal Dis* 1986;1:104-107.
13. Farmer RG, Hawk WA, Turnbull RB Jr. Clinical patterns in Crohn's disease: a statistical study of 615 cases. *Gastroenterology* 1975;68:627-635.
14. Williams DR, Collier JA, Corman ML, Nugent FW, Veidenheimer MC. Anal complications in Crohn's disease. *Dis Colon Rectum* 1981;24:22-24.
15. Fielding JF. Perianal lesions in Crohn's disease. *J R Coll Surg Edinb* 1972;17:32-37.
16. Goebell H. Perianal complications in Crohn's disease. *Neth J Med* 1990;37(suppl 1):S47-S51.
17. Greenstein AJ, Kark AE, Dreiling DA. Crohn's disease of the colon. I. Fistula in Crohn's disease of the colon, classification presenting features and management in 63 patients. *Am J Gastroenterol* 1974;62:419-429.
18. Marks CG, Ritchie JK, Lockhart-Mummery HE. Anal fistulas in Crohn's disease. *Br J Surg* 1981;68:525-527.
19. Hobbiss JH, Schofield PF. Management of perianal Crohn's disease. *J R Soc Med* 1982;75:414-417.
20. van Dongen LM, Lubbers EJ. Perianal fistulas in patients with Crohn's disease. *Arch Surg* 1986;121:1187-1190.
21. Nordgren S, Fasth S, Hulten L. Anal fistulas in Crohn's disease: incidence and outcome of surgical treatment. *Int J Colorectal Dis* 1992;7:214-218.
22. Rankin GB, Watts HD, Melnyk CS, Kelley ML Jr. National Cooperative Crohn's Disease Study: extraintestinal manifestations and perianal complications. *Gastroenterology* 1979;77:914-920.
23. Tolia V. Perianal Crohn's disease in children and adolescents. *Am J Gastroenterol* 1996;91:922-926.
24. Hellers G, Bergstrand O, Ewerth S, Holmstrom B. Occurrence and outcome after primary treatment of anal fistulae in Crohn's disease. *Gut* 1980;21:525-527.
25. Schwartz DA, Loftus EV Jr, Tremaine WJ, Panaccione R, Harnsen WS, Zinsmeister AR, Sandborn WJ. The natural history of fistulizing Crohn's disease in Olmsted County, Minnesota. *Gastroenterology* 2002;122:875-880.
26. Lockhart-Mummery HE. Symposium. Crohn's disease: anal lesions. *Dis Colon Rectum* 1975;18:200-202.
27. Lunniss PJ, Barker PG, Sultan AH, Armstrong P, Reznick RH, Bartram CI, Cottam KS, Phillips RK. Magnetic resonance imaging of fistula-in-ano. *Dis Colon Rectum* 1994;37:708-718.
28. Barker PG, Lunniss PJ, Armstrong P, Reznick RH, Cottam K, Phillips RK. Magnetic resonance imaging of fistula-in-ano: technique, interpretation and accuracy. *Clin Radiol* 1994;49:7-13.
29. deSouza NM, Hall AS, Puni R, Gilderdale DJ, Young IR, Kmiot WA. High resolution magnetic resonance imaging of the anal sphincter using a dedicated endoanal coil. Comparison of magnetic resonance imaging with surgical findings. *Dis Colon Rectum* 1996;39:926-934.
30. Hagggett PJ, Moore NR, Shearman JD, Travis SP, Jewell DP, Mortensen NJ. Pelvic and perineal complications of Crohn's disease: assessment using magnetic resonance imaging. *Gut* 1995;36:407-410.
31. Spencer JA, Chapple K, Wilson D, Ward J, Windsor AC, Ambrose NS. Outcome after surgery for perianal fistula: predictive value of MR imaging. *AJR Am J Roentgenol* 1998;171:403-406.
32. Schwartz DA, Wiersema MJ, Dudiak KM, Fletcher JG, Clain JE, Tremaine WJ, Zinsmeister AR, Norton ID, Boardman LA, Devine RM, Wolff BG, Young-Fadok TM, Diehl NN, Pemberton JH, Sandborn WJ. A comparison of endoscopic ultrasound, magnetic resonance imaging, and exam under anesthesia for evaluation of Crohn's perianal fistulas. *Gastroenterology* 2001;121:1064-1072.
33. Beets-Tan RG, Beets GL, van der Hoop AG, Kessels AG, Vliegen RF, Baeten CG, van Engelshoven JM. Preoperative MR imaging of anal fistulas: does it really help the surgeon? *Radiology* 2001;218:75-84.
34. Glass RE, Ritchie JK, Lennard-Jones JE, Hawley PR, Todd IP. Internal fistulas in Crohn's disease. *Dis Colon Rectum* 1985;28:557-561.
35. Fazio VW, Wilk P, Turnbull RB Jr, Jagelman DG. The dilemma of Crohn's disease: ileosigmoidal fistula complicating Crohn's disease. *Dis Colon Rectum* 1977;20:381-386.
36. Kuipers HC, Schulpen T. Fistulography for fistula-in-ano. Is it useful? *Dis Colon Rectum* 1985;28:103-104.
37. Pomerri F, Pittarello F, Dodi G, Pianon P, Muzzio PC. Radiologic diagnosis of anal fistulae with radio-opaque markers. *Radiol Med (Torino)* 1988;75:632-637.
38. Weisman RI, Orsay CP, Pearl RK, Abcarian H. The role of fistulography in fistula-in-ano. Report of five cases. *Dis Colon Rectum* 1991;34:181-184.
39. Schratte-Sehn AU, Lochs H, Vogelsang H, Schurawitzki H, Herold C, Schratte M. Endoscopic ultrasonography versus computed tomography in the differential diagnosis of perianorectal complications in Crohn's disease. *Endoscopy* 1993;25:582-586.
40. Van Outryve MJ, Pelckmans PA, Michiels PP, Van Maercke YM. Value of transrectal ultrasonography in Crohn's disease. *Gastroenterology* 1991;101:1171-1177.
41. Fishman EK, Wolf EJ, Jones B, Bayless TM, Siegelman SS. CT evaluation of Crohn's disease: effect on patient management. *AJR Am J Roentgenol* 1987;148:537-540.
42. Berliner L, Redmond P, Purow E, Megna D, Sottile V. Computed tomography in Crohn's disease. *Am J Gastroenterol* 1982;77:548-553.
43. Yousem DM, Fishman EK, Jones B. Crohn disease: perirectal and perianal findings at CT. *Radiology* 1988;167:331-334.
44. Goldberg HI, Gore RM, Margulis AR, Moss AA, Baker EL. Computed tomography in the evaluation of Crohn disease. *AJR Am J Roentgenol* 1983;140:277-282.
45. Kerber GW, Greenberg M, Rubin JM. Computed tomography evaluation of local and extraintestinal complications of Crohn's disease. *Gastrointest Radiol* 1984;9:143-148.
46. Laniado M, Makowiec F, Dammann F, Jehle EC, Claussen CD, Starlinger M. Perianal complications of Crohn disease: MR imaging findings. *Eur Radiol* 1997;7:1035-1042.
47. Hussain SM, Outwater EK, Joekes EC, Ulrich F, Delemarre HB, Bemelman WA, Li X, Mitchell DG. Clinical and MR imaging features of cryptoglandular and Crohn's fistulas and abscesses. *Abdom Imaging* 2000;25:67-74.
48. Skalej M, Makowiec F, Weinlich M, Jenss H, Laniado M, Starlinger M [Magnetic resonance imaging in perianal Crohn's disease]. *Dtsch Med Wochenschr* 1993;118:1791-1796.
49. Koelbel G, Schmiedl U, Majer MC, Weber P, Jenss H, Kueper K,

- Hess CF. Diagnosis of fistulae and sinus tracts in patients with Crohn disease: value of MR imaging. *AJR Am J Roentgenol* 1989;152:999–1003.
50. Van Assche G, Vanbeckevoort D, Bielen D, Coremans G, Aerden I, Noman M, D'Hoore A, Penninckx F, Marchal G, Cornillie F, Rutgeerts P. Magnetic resonance imaging of the effects of infliximab on perianal fistulizing Crohn's disease. *Am J Gastroenterol* 2003;98:332–339.
51. Agnholt J, Dahlerup J, Lyhne-Nielsen S, Buntzen S, Tottrup A, Lundorf E. Treatment of fistulizing Crohn's disease with infliximab—one year follow by MRI-scan, ultrasound, and clinical examination (abstr). *Gastroenterology* 2002;122:A613.
52. Bell SJ, Halligan S, Windsor AC, Williams AB, Wiesel P, Kamm MA. Response of fistulating Crohn's disease to infliximab treatment assessed by magnetic resonance imaging. *Aliment Pharmacol Ther* 2003;17:387–393.
53. Tio TL, Mulder CJ, Wijers OB, Sars PR, Tytgat GN. Endosonography of peri-anal and pericorectal fistula and/or abscess in Crohn's disease. *Gastrointest Endosc* 1990;36:331–336.
54. Wijers O, Tio T, Tytgat G. Endosonography (transrectal and transvaginal) in the assessment of perianorectal fistulas and abscesses: experience with 127 cases. In: Demling L, Fruhmorgan P, eds. *Non-neoplastic diseases of the anorectum*. Kluwer, London, 1992;65–78.
55. Orsoni P, Barthet M, Portier F, Panuel M, Desjeux A, Grimaud JC. Prospective comparison of endosonography, magnetic resonance imaging and surgical findings in anorectal fistula and abscess complicating Crohn's disease. *Br J Surg* 1999;86:360–364.
56. Stewart LK, McGee J, Wilson SR. Transperineal and transvaginal sonography of perianal inflammatory disease. *AJR Am J Roentgenol* 2001;177:627–632.
57. Sloots CE, Felt-Bersma RJ, Poen AC, Cuesta MA, Meuwissen SG. Assessment and classification of fistula-in-ano in patients with Crohn's disease by hydrogen peroxide enhanced transanal ultrasound. *Int J Colorectal Dis* 2001;16:292–297.
58. Solomon MJ. Fistulae and abscesses in symptomatic perianal Crohn's disease. *Int J Colorectal Dis* 1996;11:222–226.
59. van Bodegraven AA, Sloots CE, Felt-Bersma RJ, Meuwissen SG. Endosonographic evidence of persistence of Crohn's disease-associated fistulas after infliximab treatment, irrespective of clinical response. *Dis Colon Rectum* 2002;45:39–45; discussion 45–46.
60. Rasul I, Wilson SR, Cohen Z, Greenberg GR. Infliximab therapy for Crohn's disease fistulae: discordance between perianal ultrasound findings and clinical response (abstr). *Gastroenterology* 2001;120:A619.
61. Best WR, Beckett JM, Singleton JW, Kern F Jr. Development of a Crohn's disease activity index. National Cooperative Crohn's Disease Study. *Gastroenterology* 1976;70:439–444.
62. Present DH, Rutgeerts P, Targan S, Hanauer SB, Mayer L, van Hogezaand RA, Podolsky DK, Sands BE, Braakman T, DeWoody KL, Schaible TF, van Deventer SJ. Infliximab for the treatment of fistulas in patients with Crohn's disease. *N Engl J Med* 1999;340:1398–1405.
63. Sandborn WJ, Feagan BG, Hanauer SB, Lochs H, Lofberg R, Modigliani R, Present DH, Rutgeerts P, Scholmerich J, Stange EF, Sutherland LR. A review of activity indices and efficacy endpoints for clinical trials of medical therapy in adults with Crohn's disease. *Gastroenterology* 2002;122:512–530.
64. Present DH, Korelitz BI, Wisch N, Glass JL, Sachar DB, Pasternack BS. Treatment of Crohn's disease with 6-mercaptopurine. A long-term, randomized, double-blind study. *N Engl J Med* 1980;302:981–987.
65. Irvine EJ. Usual therapy improves perianal Crohn's disease as measured by a new disease activity index. McMaster IBD Study Group. *J Clin Gastroenterol* 1995;20:27–32.
66. Ursing B, Kamme C. Metronidazole for Crohn's disease. *Lancet* 1975;1:775–777.
67. Bernstein LH, Frank MS, Brandt LJ, Boley SJ. Healing of perineal Crohn's disease with metronidazole. *Gastroenterology* 1980;79:357–365.
68. Brandt LJ, Bernstein LH, Boley SJ, Frank MS. Metronidazole therapy for perineal Crohn's disease: a follow-up study. *Gastroenterology* 1982;83:383–387.
69. Schneider MU, Strobel S, Riemann JF, Demling L. [Treatment of Crohn's disease with metronidazole]. *Dtsch Med Wochenschr* 1981;106:1126–1129.
70. Schneider MU, Laudage G, Guggenmoos-Holzmann I, Riemann JF. [Metronidazole in the treatment of Crohn disease. Results of a controlled randomized prospective study]. *Dtsch Med Wochenschr* 1985;110:1724–1730.
71. Jakobovits J, Schuster MM. Metronidazole therapy for Crohn's disease and associated fistulae. *Am J Gastroenterol* 1984;79:533–540.
72. Solomon MJ, McLeod RS, O'Connor BI, Steinhart AH, Greenberg GR, Cohen Z. Combination ciprofloxacin and metronidazole in severe perianal Crohn's disease. *Can J Gastroenterol* 1993;7:571–573.
73. Turunen U, Farkkila M, Seppala K. Long-term treatment of perianal or fistulous Crohn's disease with ciprofloxacin. *Scand J Gastroenterol Suppl* 1989;24:144.
74. Turunen U, Farkkila M, Valtonen V. Long-term outcome of ciprofloxacin treatment in severe perianal or fistulous Crohn's disease (abstr). *Gastroenterology* 1993;104:A793.
75. Wolf JL. Ciprofloxacin may be useful in Crohn's disease (abstr). *Gastroenterology* 1990;98:A212.
76. Freeman CD, Klutman NE, Lamp KC. Metronidazole. A therapeutic review and update. *Drugs* 1997;54:679–708.
77. Davis R, Markham A, Balfour JA. Ciprofloxacin. An updated review of its pharmacology, therapeutic efficacy and tolerability. *Drugs* 1996;51:1019–1074.
78. Arseneau KO, Cohn SM, Cominelli F, Connors AF Jr. Cost-utility of initial medical management for Crohn's disease perianal fistulae. *Gastroenterology* 2001;120:1640–1656.
79. Feagan BG, Vandervoort MK, Wong CJ, Bernstein CN, Fedorak RN, Steinhart AH, Williams CN, Wong JB, Sandborn WJ. The health related quality of life (HRQL) of patients with fistulizing Crohn's disease (CD). *Gastroenterology* 2001;120:2601.
80. Pearson DC, May GR, Fick GH, Sutherland LR. Azathioprine and 6-mercaptopurine in Crohn disease. A meta-analysis. *Ann Intern Med* 1995;123:132–142.
81. Korelitz BI, Present DH. Favorable effect of 6-mercaptopurine on fistulae of Crohn's disease. *Dig Dis Sci* 1985;30:58–64.
82. Jeshion WC, Larsen KL, Jawad AF, Piccoli DA, Verma R, Maller ES, Baldassano RN. Azathioprine and 6-mercaptopurine for the treatment of perianal Crohn's disease in children. *J Clin Gastroenterol* 2000;30:294–298.
83. Klein M, Binder HJ, Mitchell M, Aaronson R, Spiro H. Treatment of Crohn's disease with azathioprine: a controlled evaluation. *Gastroenterology* 1974;66:916–922.
84. Rosenberg JL, Levin B, Wall AJ, Kirsner JB. A controlled trial of azathioprine in Crohn's disease. *Am J Dig Dis* 1975;20:721–726.
85. Rhodes J, Bainton D, Beck P, Campbell H. Controlled trial of azathioprine in Crohn's disease. *Lancet* 1971;2:1273–1276.
86. Willoughby JM, Beckett J, Kumar PJ, Dawson AM. Controlled trial of azathioprine in Crohn's disease. *Lancet* 1971;2:944–947.
87. Present DH, Meltzer SJ, Krumholz MP, Wolke A, Korelitz BI. 6-Mercaptopurine in the management of inflammatory bowel disease: short- and long-term toxicity. *Ann Intern Med* 1989;111:641–649.
88. Dayharsh GA, Loftus EV Jr, Sandborn WJ, Tremaine WJ, Zinsmeister AR, Witzig TE, Macon WR, Burgart LJ. Epstein-Barr virus

- positive lymphoma in patients with inflammatory bowel disease treated with azathioprine or 6-mercaptopurine. *Gastroenterology* 2002;122:72–77.
89. Sands B, Van Deventer S, Bernstein C, Kamm M, Rachmilewicz D, Chey W, Lashner B, Wolf D, Blank M, Wild G, Fedorak R, Feagan B, Anderson F, Marsters P, Rutgeerts P. Long-term treatment of fistulizing Crohn's disease: response to infliximab in the ACCENT II trial through 54 weeks (abstr). *Gastroenterology* 2002;122:A81.
  90. Ricart E, Panaccione R, Loftus EV, Tremaine WJ, Sandborn WJ. Infliximab for Crohn's disease in clinical practice at the Mayo Clinic: the first 100 patients. *Am J Gastroenterol* 2001;96:722–729.
  91. Cohen RD, Tsang JF, Hanauer SB. Infliximab in Crohn's disease: first anniversary clinical experience. *Am J Gastroenterol* 2000;95:3469–3477.
  92. Farrell RJ, Shah SA, Lodhavia PJ, Alsahli M, Falchuk KR, Michetti P, Peppercorn MA. Clinical experience with infliximab therapy in 100 patients with Crohn's disease. *Am J Gastroenterol* 2000;95:3490–3497.
  93. Poritz LS, Rowe WA, Koltun WA. Remicade does not abolish the need for surgery in fistulizing Crohn's disease. *Dis Colon Rectum* 2002;45:771–775.
  94. Regueiro M, Mardini H. Treatment of perianal fistulizing Crohn's disease with infliximab alone or as an adjunct for exam under anesthesia with seton placement. *Inflamm Bowel Dis* 2003;9:98–103.
  95. Sandborn WJ, Hanauer SB. Antitumor necrosis factor therapy for inflammatory bowel disease: a review of agents, pharmacology, clinical results, and safety. *Inflamm Bowel Dis* 1999;5:119–133.
  96. Schaible TF. Long term safety of infliximab. *Can J Gastroenterol* 2000;14(suppl C):29C–32C.
  97. Remicade (infliximab) for IV injection. Package Insert, 2002.
  98. Sandborn WJ, Hanauer SB. Infliximab in the treatment of Crohn's disease: a user's guide for clinicians. *Am J Gastroenterol* 2002;97:2962–2972.
  99. Keane J, Gershon S, Wise RP, Mirabile-Levens E, Kasznica J, Schwieterman WD, Siegel JN, Braun MM. Tuberculosis associated with infliximab, a tumor necrosis factor alpha-neutralizing agent. *N Engl J Med* 2001;345:1098–1104.
  100. Warris A, Bjorneklett A, Gaustad P. Invasive pulmonary aspergillosis associated with infliximab therapy. *N Engl J Med* 2001;344:1099–1100.
  101. Nakelchik M, Mangino JE. Reactivation of histoplasmosis after treatment with infliximab. *Am J Med* 2002;112:78.
  102. Kamath BM, Mamula P, Baldassano RN, Markowitz JE. Listeria meningitis after treatment with infliximab. *J Pediatr Gastroenterol Nutr* 2002;34:410–412.
  103. Morelli J, Wilson FA. Does administration of infliximab increase susceptibility to listeriosis? *Am J Gastroenterol* 2000;95:841–842.
  104. Fukushima T, Sugita A, Masuzawa S, Yamazaki Y, Tsuchiya S. Effects of cyclosporin A on active Crohn's disease. *Gastroenterol Jpn* 1989;24:12–15.
  105. Lichtiger S. Cyclosporine therapy in inflammatory bowel disease: open-label experience. *Mt Sinai J Med* 1990;57:315–319.
  106. Hanauer SB, Smith MB. Rapid closure of Crohn's disease fistulas with continuous intravenous cyclosporin A. *Am J Gastroenterol* 1993;88:646–649.
  107. Present DH, Lichtiger S. Efficacy of cyclosporine in treatment of fistula of Crohn's disease. *Dig Dis Sci* 1994;39:374–380.
  108. Markowitz J, Rosa J, Grancher K, Aiges H, Daum F. Long-term 6-mercaptopurine treatment in adolescents with Crohn's disease. *Gastroenterology* 1990;99:1347–1351.
  109. Abreu-Martin J, Vasiliauskas E, Gaiennie J, Voigt B, Targan SR. Continuous infusion cyclosporine is effective for acute severe Crohn's disease...but for how long (abstr)? *Gastroenterology* 1996;110:A851.
  110. O'Neill J, Pathmakanthan S, Goh J, Costello S, MacMathuna P, O'Connell R, Crowe J, Lennon J. Cyclosporine A induces remission in fistulous Crohn's disease but relapse occurs upon cessation of treatment (abstr). *Gastroenterology* 1997;112:A1056.
  111. Hinterleitner TA, Petritsch W, Aichbichler B, Fickert P, Ranner G, Krejs GJ. Combination of cyclosporine, azathioprine and prednisolone for perianal fistulas in Crohn's disease. *Gastroenterology* 1997;35:603–608.
  112. Egan LJ, Sandborn WJ, Tremaine WJ. Clinical outcome following treatment of refractory inflammatory and fistulizing Crohn's disease with intravenous cyclosporine. *Am J Gastroenterol* 1998;93:442–448.
  113. Gurudu SR, Griffel LH, Gialanella RJ, Das KM. Cyclosporine therapy in inflammatory bowel disease: short-term and long-term results. *J Clin Gastroenterol* 1999;29:151–154.
  114. Sandborn WJ. A critical review of cyclosporine therapy in inflammatory bowel disease. *Inflamm Bowel Dis* 1995;1:48–63.
  115. Sandborn WJ. Preliminary report on the use of oral tacrolimus (FK506) in the treatment of complicated proximal small bowel and fistulizing Crohn's disease. *Am J Gastroenterol* 1997;92:876–879.
  116. Fellermann K, Ludwig D, Stahl M, David-Walek T, Stange EF. Steroid-unresponsive acute attacks of inflammatory bowel disease: immunomodulation by tacrolimus (FK506). *Am J Gastroenterol* 1998;93:1860–1866.
  117. Lowry PW, Weaver AL, Tremaine WJ, Sandborn WJ. Combination therapy with oral tacrolimus (FK506) and azathioprine or 6-mercaptopurine for treatment-refractory Crohn's disease perianal fistulae. *Inflamm Bowel Dis* 1999;5:239–245.
  118. Ierardi E, Principi M, Rendina M, Francavilla R, Ingrosso M, Pisani A, Amoroso A, Panella C, Francavilla A. Oral tacrolimus (FK 506) in Crohn's disease complicated by fistulae of the perineum. *J Clin Gastroenterol* 2000;30:200–202.
  119. Sandborn WJ, Present DH, Isaacs KL, Wolf DC, Greenberg E, Hanauer SB, Feagan BG, Mayer L, Johnson T, Galanko J, Martin C, Sandler RS. Tacrolimus for the treatment of fistulas in patients with Crohn's disease: a randomized, placebo-controlled trial. *Gastroenterology* 2003;125:380–388.
  120. Voitk AJ, Echave V, Brown RA, Gurd FN. Use of elemental diet during the adaptive stage of short gut syndrome. *Gastroenterology* 1973;65:419–426.
  121. Segal AW, Levi AJ, Loewi G. Levamisole in the treatment of Crohn's disease. *Lancet* 1977;2:382–385.
  122. Axelsson C, Jarnum S. Assessment of the therapeutic value of an elemental diet in chronic inflammatory bowel disease. *Scand J Gastroenterol* 1977;12:89–95.
  123. Russell RI, Hall MJ. Elemental diet therapy in the management of complicated Crohn's disease. *Scott Med J* 1979;24:291–295.
  124. Teahon K, Bjarnason I, Pearson M, Levi AJ. Ten years' experience with an elemental diet in the management of Crohn's disease. *Gut* 1990;31:1133–1137.
  125. Jones VA. Comparison of total parenteral nutrition and elemental diet in induction of remission of Crohn's disease. Long-term maintenance of remission by personalized food exclusion diets. *Dig Dis Sci* 1987;32:100S–107S.
  126. Fukuda Y, Kosaka T, Okui M, Hirakawa H, Shimoyama T. Efficacy of nutritional therapy for active Crohn's disease. *J Gastroenterol* 1995;30(suppl 8):83–87.
  127. Milewski PJ, Irving MH. Parenteral nutrition in Crohn's disease. *Dis Colon Rectum* 1980;23:395–400.
  128. Harford FJ Jr, Fazio VW. Total parenteral nutrition as primary therapy for inflammatory disease of the bowel. *Dis Colon Rectum* 1978;21:555–557.

129. Greenberg GR, Fleming CR, Jeejeebhoy KN, Rosenberg IH, Sales D, Tremaine WJ. Controlled trial of bowel rest and nutritional support in the management of Crohn's disease. *Gut* 1988;29:1309-1315.
130. Calam J, Crooks PE, Walker RJ. Elemental diets in the management of Crohn's perianal fistulae. *JPEN J Parenter Enteral Nutr* 1980;4:4-8.
131. Horgan K. Initial experience with mycophenolate mofetil in the treatment of severe inflammatory bowel disease (abstr). *Gastroenterology* 1997;112:A999.
132. Fickert P, Hinterleitner TA, Wenzl HH, Aichbichler BW, Petritsch W. Mycophenolate mofetil in patients with Crohn's disease. *Am J Gastroenterol* 1998;93:2529-2532.
133. Mahadevan U, Marion J, Present D. The place of methotrexate in the treatment of refractory Crohn's disease (abstr). *Gastroenterology* 1997;112:A1031.
134. Vasiliasukas EA, Kam LY, Abreu-Martin MT, Hassard PV, Papadakis KA, Yang H, Zeldis JB, Targan SR. An open-label pilot study of low-dose thalidomide in chronically active, steroid-dependent Crohn's disease. *Gastroenterology* 1999;117:1278-1287.
135. Ehrenpreis ED, Kane SV, Cohen LB, Cohen RD, Hanauer SB. Thalidomide therapy for patients with refractory Crohn's disease: an open-label trial. *Gastroenterology* 1999;117:1271-1277.
136. Vaughan D, Drumm B. Treatment of fistulas with granulocyte colony-stimulating factor in a patient with Crohn's disease. *N Engl J Med* 1999;340:239-240.
137. Korzenik J, Dieckgraefe B. Immunostimulation in Crohn's disease: results of a pilot study of G-CSF (R-Methug-CSF) in mucosal and fistulizing Crohn's disease (abstr). *Gastroenterology* 2000;118:A874.
138. Dieckgraefe BK, Korzenik JR. Treatment of active Crohn's disease with recombinant human granulocyte-macrophage colony-stimulating factor. *Lancet* 2002;360:1478-1480.
139. Brady CE III, Cooley BJ, Davis JC. Healing of severe perineal and cutaneous Crohn's disease with hyperbaric oxygen. *Gastroenterology* 1989;97:756-760.
140. Brady CE III. Hyperbaric oxygen and perineal Crohn's disease: a follow-up. *Gastroenterology* 1993;105:1264.
141. Nelson EW Jr, Bright DE, Villar LF. Closure of refractory perineal Crohn's lesion. Integration of hyperbaric oxygen into case management. *Dig Dis Sci* 1990;35:1561-1565.
142. Lavy A, Weisz G, Adir Y, Ramon Y, Melamed Y, Eidelman S. Hyperbaric oxygen for perianal Crohn's disease. *J Clin Gastroenterol* 1994;19:202-205.
143. Colombel JF, Mathieu D, Bouault JM, Lesage X, Zavadil P, Quandalle P, Cortot A. Hyperbaric oxygenation in severe perineal Crohn's disease. *Dis Colon Rectum* 1995;38:609-614.
144. Buchmann P, Keighley MR, Allan RN, Thompson H, Alexander-Williams J. Natural history of perianal Crohn's disease. Ten year follow-up: a plea for conservatism. *Am J Surg* 1980;140:642-644.
145. Alexander-Williams J, Buchmann P. Perianal Crohn's disease. *World J Surg* 1980;4:203-208.
146. Wolff BG, Culp CE, Beart RW Jr, Ilstrup DM, Ready RL. Anorectal Crohn's disease. A long-term perspective. *Dis Colon Rectum* 1985;28:709-711.
147. Pescatori M, Interisano A, Basso L, Arcana F, Buffatti P, Di Bella F, Doldi A, Forcheri V, Gaetini R, Pera A, et al. Management of perianal Crohn's disease. Results of a multicenter study in Italy. *Dis Colon Rectum* 1995;38:121-124.
148. Makowiec F, Jehle EC, Starlinger M. Clinical course of perianal fistulas in Crohn's disease. *Gut* 1995;37:696-701.
149. Schwartz DA, Pemberton JH, Sandborn WJ. Diagnosis and treatment of perianal fistulas in Crohn disease. *Ann Intern Med* 2001;135:906-918.
150. Taylor BA, Williams GT, Hughes LE, Rhodes J. The histology of anal skin tags in Crohn's disease: an aid to confirmation of the diagnosis. *Int J Colorectal Dis* 1989;4:197-199.
151. Jeffery PJ, Parks AG, Ritchie JK. Treatment of hemorrhoids in patients with inflammatory bowel disease. *Lancet* 1977;1:1084-1085.
152. Morrison JG, Gathright JB Jr, Ray JE, Ferrari BT, Hicks TC, Timmcke AE. Surgical management of anorectal fistulas in Crohn's disease. *Dis Colon Rectum* 1989;32:492-496.
153. Wolkomir AF, Luchtefeld MA. Surgery for symptomatic hemorrhoids and anal fissures in Crohn's disease. *Dis Colon Rectum* 1993;36:545-547.
154. Allan A, Keighley MR. Management of perianal Crohn's disease. *World J Surg* 1988;12:198-202.
155. Sohn N, Korelitz BI, Weinstein MA. Anorectal Crohn's disease: definitive surgery for fistulas and recurrent abscesses. *Am J Surg* 1980;139:394-397.
156. Sweeney JL, Ritchie JK, Nicholls RJ. Anal fissure in Crohn's disease. *Br J Surg* 1988;75:56-57.
157. Fleshner PR, Schoetz DJ Jr, Roberts PL, Murray JJ, Collier JA, Veidenheimer MC. Anal fissure in Crohn's disease: a plea for aggressive management. *Dis Colon Rectum* 1995;38:1137-1143.
158. Linares L, Moreira LF, Andrews H, Allan RN, Alexander-Williams J, Keighley MR. Natural history and treatment of anorectal strictures complicating Crohn's disease. *Br J Surg* 1988;75:653-655.
159. Alexander-Williams J, Allan A, Morel P, Hawker PC, Dykes PW, O'Connor H. The therapeutic dilatation of enteric strictures due to Crohn's disease. *Ann R Coll Surg Engl* 1986;68:95-97.
160. Bernard D, Morgan S, Tasse D. Selective surgical management of Crohn's disease of the anus. *Can J Surg* 1986;29:318-321.
161. Lockhart-Mummery HE. Anal lesions in Crohn's disease. *Br J Surg* 1985;72(suppl):S95-S96.
162. Homan WP, Tang C, Thorgjarnarson B. Anal lesions complicating Crohn disease. *Arch Surg* 1976;111:1333-1335.
163. Williams JG, Hughes LE. Abdominoperineal resection for severe perianal Crohn's disease. *Dis Colon Rectum* 1990;33:402-407.
164. White RA, Eisenstat TE, Rubin RJ, Salvati EP. Seton management of complex anorectal fistulas in patients with Crohn's disease. *Dis Colon Rectum* 1990;33:587-589.
165. Levien DH, Surrell J, Mazier WP. Surgical treatment of anorectal fistula in patients with Crohn's disease. *Surg Gynecol Obstet* 1989;169:133-136.
166. Pritchard TJ, Schoetz DJ Jr, Roberts PL, Murray JJ, Collier JA, Veidenheimer MC. Perirectal abscess in Crohn's disease. Drainage and outcome. *Dis Colon Rectum* 1990;33:933-937.
167. Fry RD, Shemesh EI, Kodner IJ, Timmcke A. Techniques and results in the management of anal and perianal Crohn's disease. *Surg Gynecol Obstet* 1989;168:42-48.
168. Kangas E. Anal lesions complicating Crohn's disease. *Ann Chir Gynaecol* 1991;80:336-339.
169. Makowiec F, Jehle EC, Becker HD, Starlinger M. Perianal abscess in Crohn's disease. *Dis Colon Rectum* 1997;40:443-450.
170. Williamson PR, Hellinger MD, Larach SW, Ferrara A. Twenty-year review of the surgical management of perianal Crohn's disease. *Dis Colon Rectum* 1995;38:389-392.
171. Fuhrman GM, Larach SW. Experience with perirectal fistulas in patients with Crohn's disease. *Dis Colon Rectum* 1989;32:847-848.
172. Koganei K, Sugita A, Harada H, Fukushima T, Shimada H. Seton treatment for perianal Crohn's fistulas. *Surg Today* 1995;25:32-36.
173. Williams JG, Rothenberger DA, Nemer FD, Goldberg SM. Fistula-

- in-ano in Crohn's disease. Results of aggressive surgical treatment. *Dis Colon Rectum* 1991;34:378-384.
174. Winter AM, Banks PA, Petros JG. Healing of transsphincteric perianal fistulas in Crohn's disease using a new technique. *Am J Gastroenterol* 1993;88:2022-2025.
  175. Halme L, Sainio AP. Factors related to frequency, type, and outcome of anal fistulas in Crohn's disease. *Dis Colon Rectum* 1995;38:55-59.
  176. Scott HJ, Northover JM. Evaluation of surgery for perianal Crohn's fistulas. *Dis Colon Rectum* 1996;39:1039-1043.
  177. McKee RF, Keenan RA. Perianal Crohn's disease—is it all bad news? *Dis Colon Rectum* 1996;39:136-142.
  178. Sangwan YP, Schoetz DJ Jr, Murray JJ, Roberts PL, Collier JA. Perianal Crohn's disease. Results of local surgical treatment. *Dis Colon Rectum* 1996;39:529-535.
  179. Michelassi F, Melis M, Rubin M, Hurst RD. Surgical treatment of anorectal complications in Crohn's disease. *Surgery* 2000;128:597-603.
  180. Platell C, Mackay J, Collopy B, Fink R, Ryan P, Woods R. Anal pathology in patients with Crohn's disease. *Aust N Z J Surg* 1996;66:5-9.
  181. Sugita A, Koganei K, Harada H, Yamazaki Y, Fukushima T, Shimada H. Surgery for Crohn's anal fistulas. *J Gastroenterol* 1995;30(suppl 8):143-146.
  182. Williams JG, MacLeod CA, Rothenberger DA, Goldberg SM. Seton treatment of high anal fistulae. *Br J Surg* 1991;78:1159-1161.
  183. Faucheron JL, Saint-Marc O, Guibert L, Parc R. Long-term seton drainage for high anal fistulas in Crohn's disease—a sphincter-saving operation? *Dis Colon Rectum* 1996;39:208-211.
  184. Pearl RK, Andrews JR, Orsay CP, Weisman RI, Prasad ML, Nelson RL, Cintron JR, Abcarian H. Role of the seton in the management of anorectal fistulas. *Dis Colon Rectum* 1993;36:573-577; discussion 577-579.
  185. Matos D, Lunniss PJ, Phillips RK. Total sphincter conservation in high fistula in ano: results of a new approach. *Br J Surg* 1993;80:802-804.
  186. Jones IT, Fazio VW, Jagelman DG. The use of transanal rectal advancement flaps in the management of fistulas involving the anorectum. *Dis Colon Rectum* 1987;30:919-923.
  187. Lewis P, Bartolo DC. Treatment of trans-sphincteric fistulae by full thickness anorectal advancement flaps. *Br J Surg* 1990;77:1187-1189.
  188. Makowiec F, Jehle EC, Becker HD, Starlinger M. Clinical course after transanal advancement flap repair of perianal fistula in patients with Crohn's disease. *Br J Surg* 1995;82:603-606.
  189. Joo JS, Weiss EG, Noguera JJ, Wexner SD. Endorectal advancement flap in perianal Crohn's disease. *Am Surg* 1998;64:147-150.
  190. Robertson WG, Mangione JS. Cutaneous advancement flap closure: alternative method for treatment of complicated anal fistulas. *Dis Colon Rectum* 1998;41:884-886; discussion 886-887.
  191. Marchesa P, Hull TL, Fazio VW. Advancement sleeve flaps for treatment of severe perianal Crohn's disease. *Br J Surg* 1998;85:1695-1698.
  192. Harper PH, Kettlewell MG, Lee EC. The effect of split ileostomy on perianal Crohn's disease. *Br J Surg* 1982;69:608-610.
  193. Zelas P, Jagelman DG. Loop ileostomy in the management of Crohn's colitis in the debilitated patient. *Ann Surg* 1980;191:164-168.
  194. Grant DR, Cohen Z, McLeod RS. Loop ileostomy for anorectal Crohn's disease. *Can J Surg* 1986;29:32-35.
  195. Sher ME, Bauer JJ, Gorphine S, Gelernt I. Low Hartmann's procedure for severe anorectal Crohn's disease. *Dis Colon Rectum* 1992;35:975-980.
  196. Yamamoto T, Allan RN, Keighley MR. Effect of fecal diversion alone on perianal Crohn's disease. *World J Surg* 2000;24:1258-1262; discussion 1262-1263.
  197. Orkin BA, Telander RL. The effect of intra-abdominal resection or fecal diversion on perianal disease in pediatric Crohn's disease. *J Pediatr Surg* 1985;20:343-347.
  198. Hudson CN. Acquired fistulae between the intestine and the vagina. *Ann R Coll Surg Engl* 1970;46:20-40.
  199. Faulconer HT, Muldoon JP. Rectovaginal fistula in patients with colitis: review and report of a case. *Dis Colon Rectum* 1975;18:413-415.
  200. Givel JC, Hawker P, Allan RN, Alexander-Williams J. Enterovaginal fistulas associated with Crohn's disease. *Surg Gynecol Obstet* 1982;155:494-496.
  201. Bandy LC, Addison A, Parker RT. Surgical management of rectovaginal fistulas in Crohn's disease. *Am J Obstet Gynecol* 1983;147:359-363.
  202. Radcliffe AG, Ritchie JK, Hawley PR, Lennard-Jones JE, Northover JM. Anovaginal and rectovaginal fistulas in Crohn's disease. *Dis Colon Rectum* 1988;31:94-99.
  203. O'Leary DP, Milroy CE, Durdey P. Definitive repair of anovaginal fistula in Crohn's disease. *Ann R Coll Surg Engl* 1998;80:250-252.
  204. Tuxen PA, Castro AF. Rectovaginal fistula in Crohn's disease. *Dis Colon Rectum* 1979;22:58-62.
  205. Cohen JL, Stricker JW, Schoetz DJ Jr, Collier JA, Veidenheimer MC. Rectovaginal fistula in Crohn's disease. *Dis Colon Rectum* 1989;32:825-828.
  206. Wiskind AK, Thompson JD. Transverse transperineal repair of rectovaginal fistulas in the lower vagina. *Am J Obstet Gynecol* 1992;167:694-699.
  207. Farkas AM, Gingold BS. Repair of rectovaginal fistula in Crohn's disease by rectal mucosal advancement flap. *Mt Sinai J Med* 1983;50:420-423.
  208. Hesterberg R, Schmidt WU, Muller F, Roher HD. Treatment of anovaginal fistulas with an anocutaneous flap in patients with Crohn's disease. *Int J Colorectal Dis* 1993;8:51-54.
  209. Hull TL, Fazio VW. Surgical approaches to low anovaginal fistula in Crohn's disease. *Am J Surg* 1997;173:95-98.
  210. Ozuner G, Hull TL, Cartmill J, Fazio VW. Long-term analysis of the use of transanal rectal advancement flaps for complicated anorectal/vaginal fistulas. *Dis Colon Rectum* 1996;39:10-14.
  211. Simmang CL, Lacey SW, Huber PJ Jr. Rectal sleeve advancement: repair of rectovaginal fistula associated with anorectal stricture in Crohn's disease. *Dis Colon Rectum* 1998;41:787-789.
  212. Sher ME, Bauer JJ, Gelernt I. Surgical repair of rectovaginal fistulas in patients with Crohn's disease: transvaginal approach. *Dis Colon Rectum* 1991;34:641-648.
  213. Brandt LJ, Estabrook SG, Reinus JF. Results of a survey to evaluate whether vaginal delivery and episiotomy lead to perineal involvement in women with Crohn's disease. *Am J Gastroenterol* 1995;90:1918-1922.
  214. Illyckyji A, Blanchard JF, Rawsthorne P, Bernstein CN. Perianal Crohn's disease and pregnancy: role of the mode of delivery. *Am J Gastroenterol* 1999;94:3274-3278.
  215. Ky A, Sohn N, Weinstein MA, Korelitz BI. Carcinoma arising in anorectal fistulas of Crohn's disease. *Dis Colon Rectum* 1998;41:992-996.
  216. Church JM, Weakley FL, Fazio VW, Sebek BA, Achkar E, Carwell M. The relationship between fistulas in Crohn's disease and associated carcinoma. Report of four cases and review of the literature. *Dis Colon Rectum* 1985;28:361-366.
  217. Chaikhouni A, Regueyra FI, Stevens JR. Adenocarcinoma in perineal fistulas of Crohn's disease. *Dis Colon Rectum* 1981;24:639-643.
  218. Ying LT, Hurlbut DJ, Depew WT, Boag AH, Taguchi K. Primary

- adenocarcinoma in an enterocutaneous fistula associated with Crohn's disease. *Can J Gastroenterol* 1998;12:265-269.
219. Korelitz BI. Carcinoma arising in Crohn's disease fistulae: another concern warranting another type of surveillance. *Am J Gastroenterol* 1999;94:2337-2339.
220. Wong NA, Shirazi T, Hamer-Hodges DW, Corfield AP, Lessells AM. Adenocarcinoma arising within a Crohn's-related anorectal fistula: a form of anal gland carcinoma? *Histopathology* 2002;40:302-304.
221. Kulaylat MN, Gallina G, Bem J, Zeid M. Carcinoma arising in anorectal fistulas of Crohn's disease. *Dis Colon Rectum* 1999;42:826-828.
222. Hanauer SB, Sandborn W. The Practice Parameters Committee of the American College of Gastroenterology. Management of Crohn's disease in adults. *Am J Gastroenterol* 2001;96:635-643.
223. Bauer JJ, Sher ME, Jaffin H, Present D, Gelerent I. Transvaginal approach for repair of rectovaginal fistulae complicating Crohn's disease. *Ann Surg* 1991;213:151-158.

---

Address requests for reprints to: Chair, Clinical Practice Committee, AGA National Office, c/o Membership Department, 4930 Del Ray Avenue, Bethesda, Maryland 20814. Fax: (301) 654-5920.

W. J. S. has consulted for Prometheus Laboratories, GlaxoSmithKline, Centocor, Novartis, and Fujisawa. He has received research support from Prometheus Laboratories, Schering-Plough, Centocor, and Fujisawa. He has participated in continuing medical education events indirectly sponsored by Prometheus Laboratories, Schering-Plough, and Centocor. B. G. F. has consulted for Centocor and Novartis. He has received research support from Schering-Plough and Centocor. He has participated in continuing medical education events indirectly sponsored by Schering-Plough and Centocor. S. B. H. has consulted for and received research support from Centocor. He has participated in continuing medical education events indirectly sponsored by Schering-Plough and Centocor.

The Clinical Practice Committee thanks the following individuals whose critiques of this review paper provided valuable guidance to the authors: Jeffrey L. Barnett, M.D., Geert D'Haens, M.D., Ph.D., Francis A. Farraye, M.D., M.Sc., Jeffrey A. Katz, M.D., and Gary R. Lichtenstein, M.D.